



**30 ANNI DI OSTEOPATIA IN ITALIA**  
SVILUPPO, RICERCA E IDENTITÀ  
24 - 25 - 26 GIUGNO 2022

# L'osteopatia nei disordini cranio-mandibolo-posturali

Stefano Colasanto  
DDS D.O.

# **Qual è il limite di efficacia delle manovre e tecniche osteopatiche?**

**Il limite dell'osteopatia  
nel ridare mobilità al  
corpo è dato dalle  
funzioni obbligatorie e  
stereotipate**

COMPUTER

LETTO

AUTO

TELEFONO

LAVORO

HOBBY

SPORT

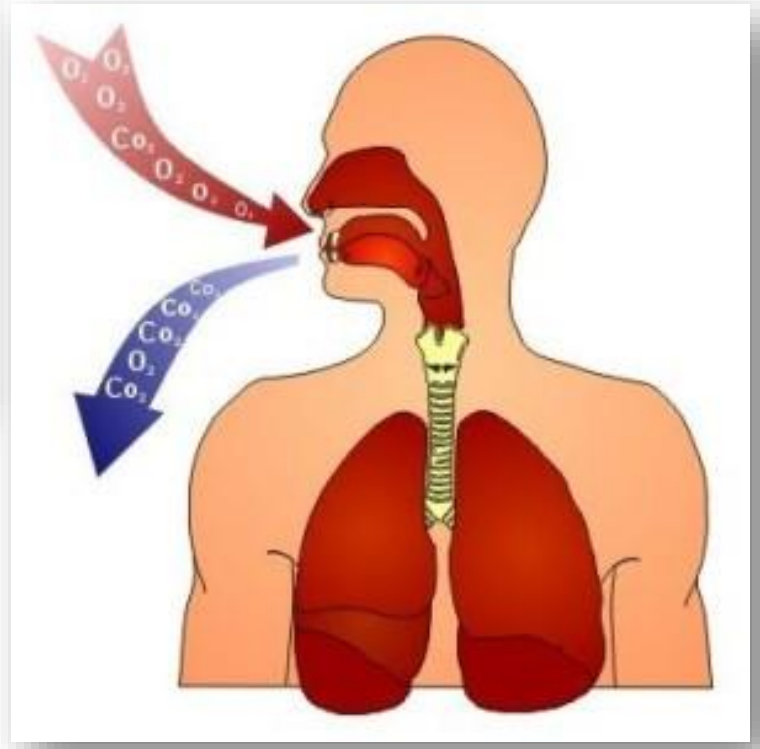
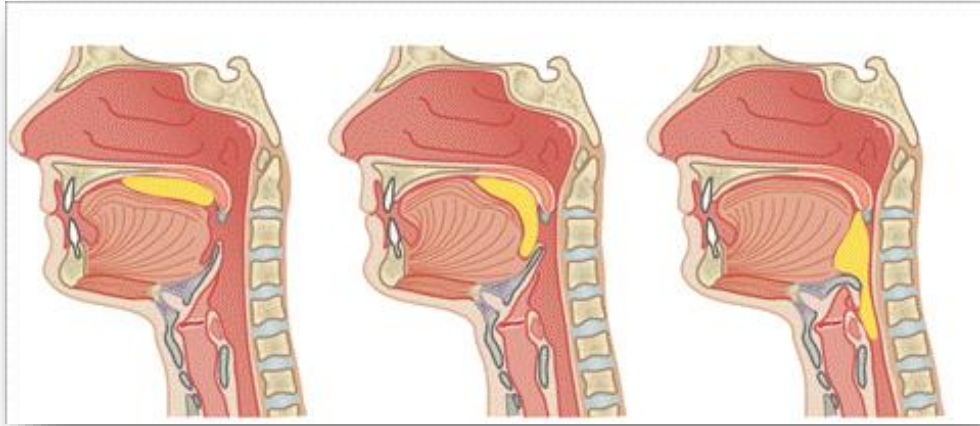
ECC. ECC.

# **Esistono funzioni obbligatorie e stereotipate in natura?**

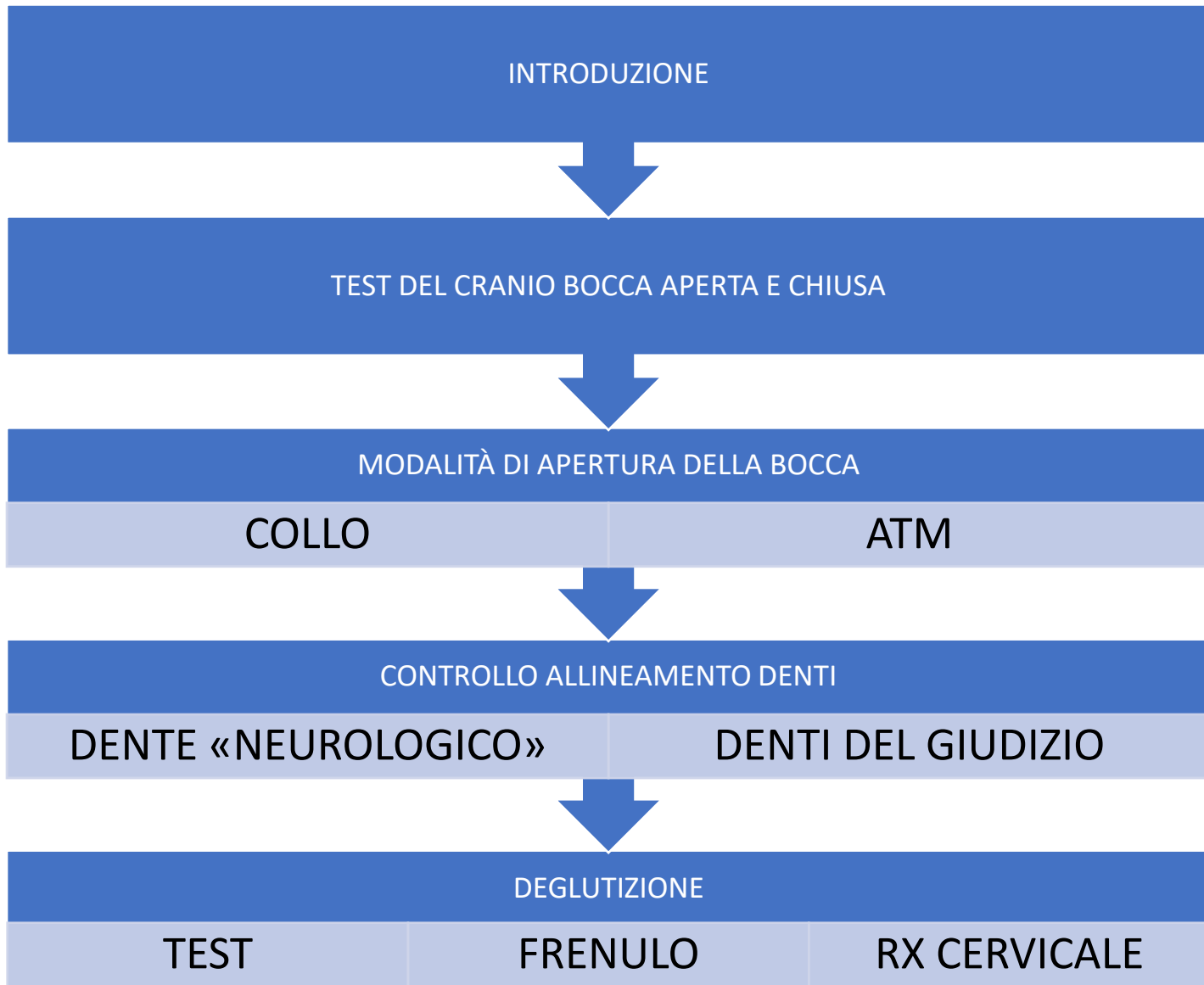
RESPIRARE

MASTICARE

DEGLUTIRE



# PROGRAMMA DEL WORKSHOP



INTRODUZIONE



TEST DEL CRANIO BOCCA APERTA E CHIUSA



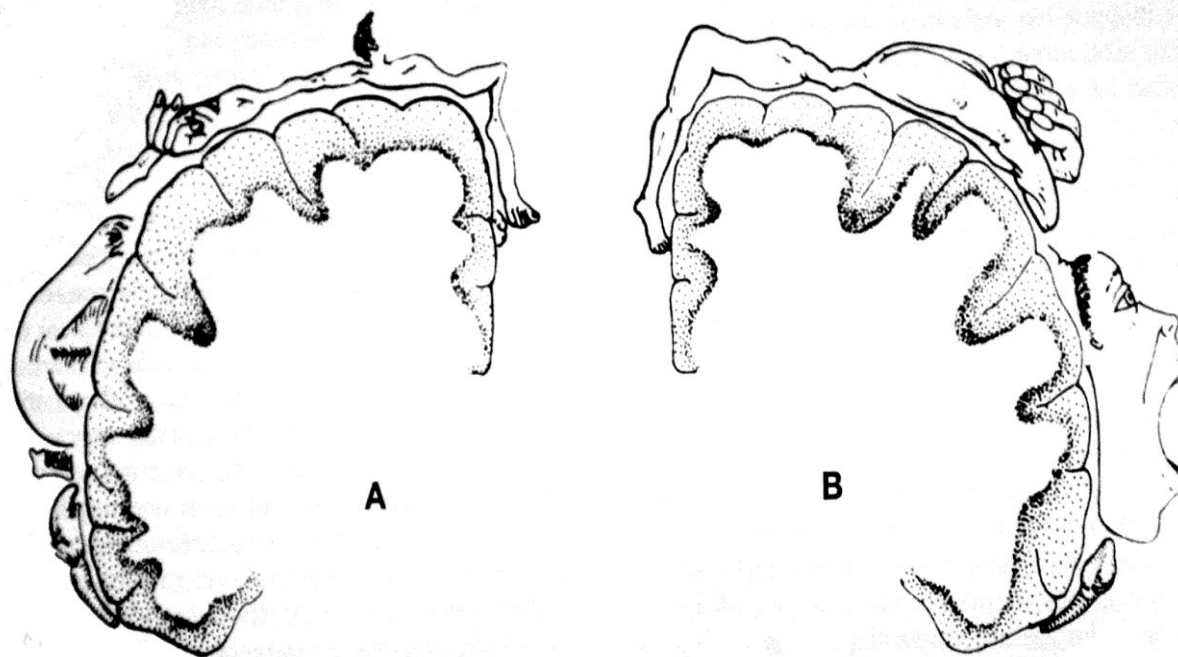
MODALITÀ DI APERTURA DELLA BOCCA



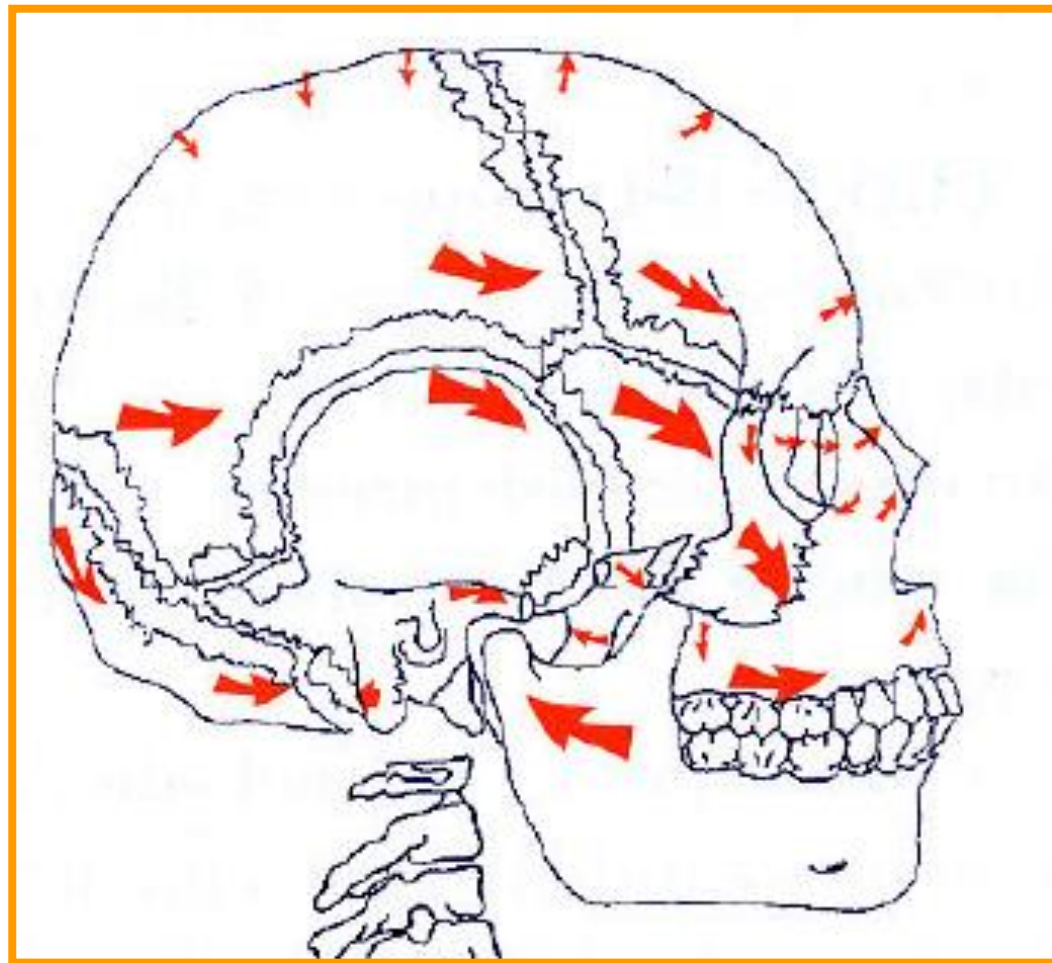
CONTROLLO ALLINEAMENTO DENTI



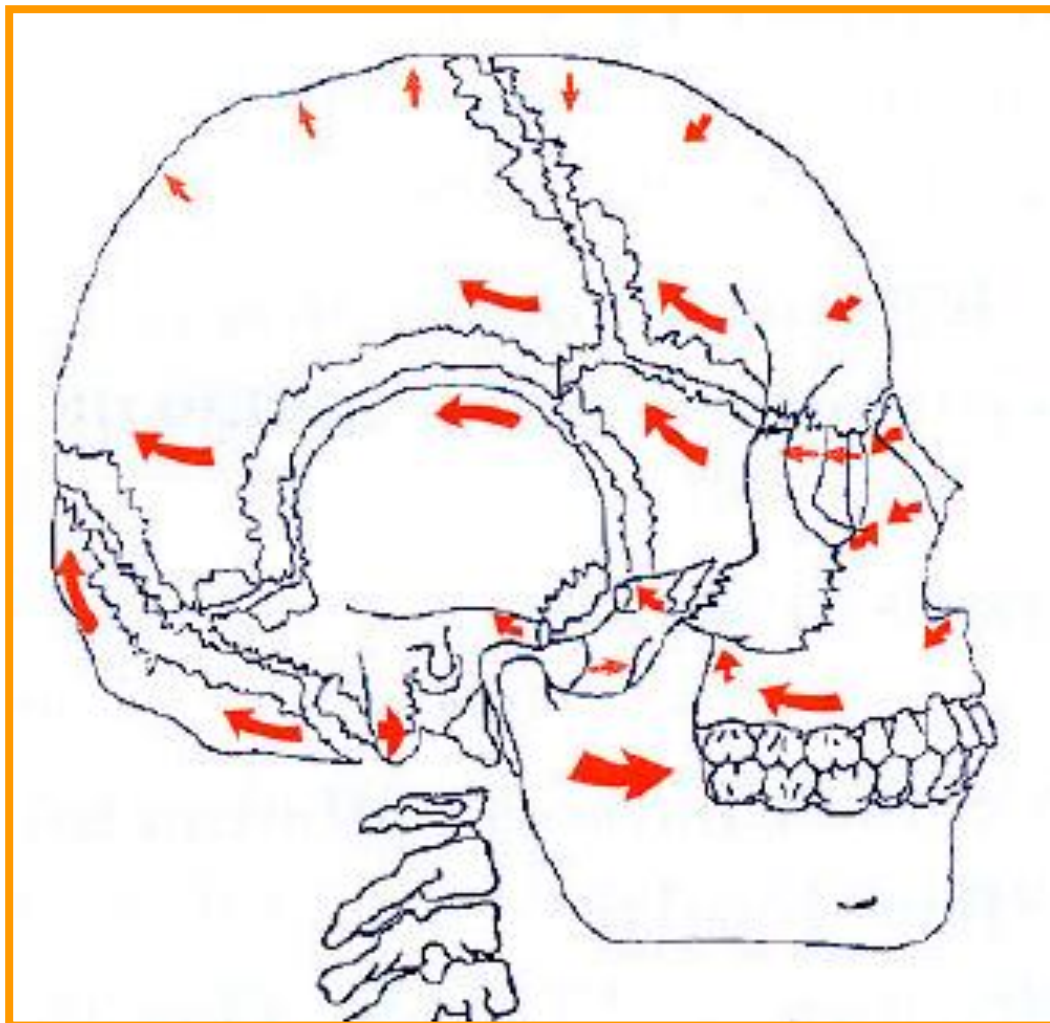
DEGLUTIZIONE



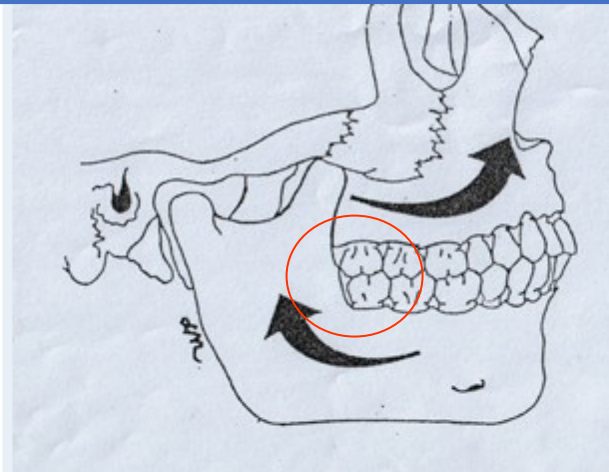
9-19 Omuncolo: (A) sensoriale, (B) motorio. Tratto dal testo di Penfield e Rasmussen<sup>51</sup> Cerebral Cortex of Man, the Macmillan Co.



# FLESSIONE



# ESTENSIONE



Mouvements des arcades dentaires en inspiration.

- De ce fait les molaires mandibulaires s'écartent du plan sagittal et s'élèvent relativement en reculant.
- au niveau supérieur : les maxillaires avancent relativement (sphénoïdes) et s'abaissent relativement.

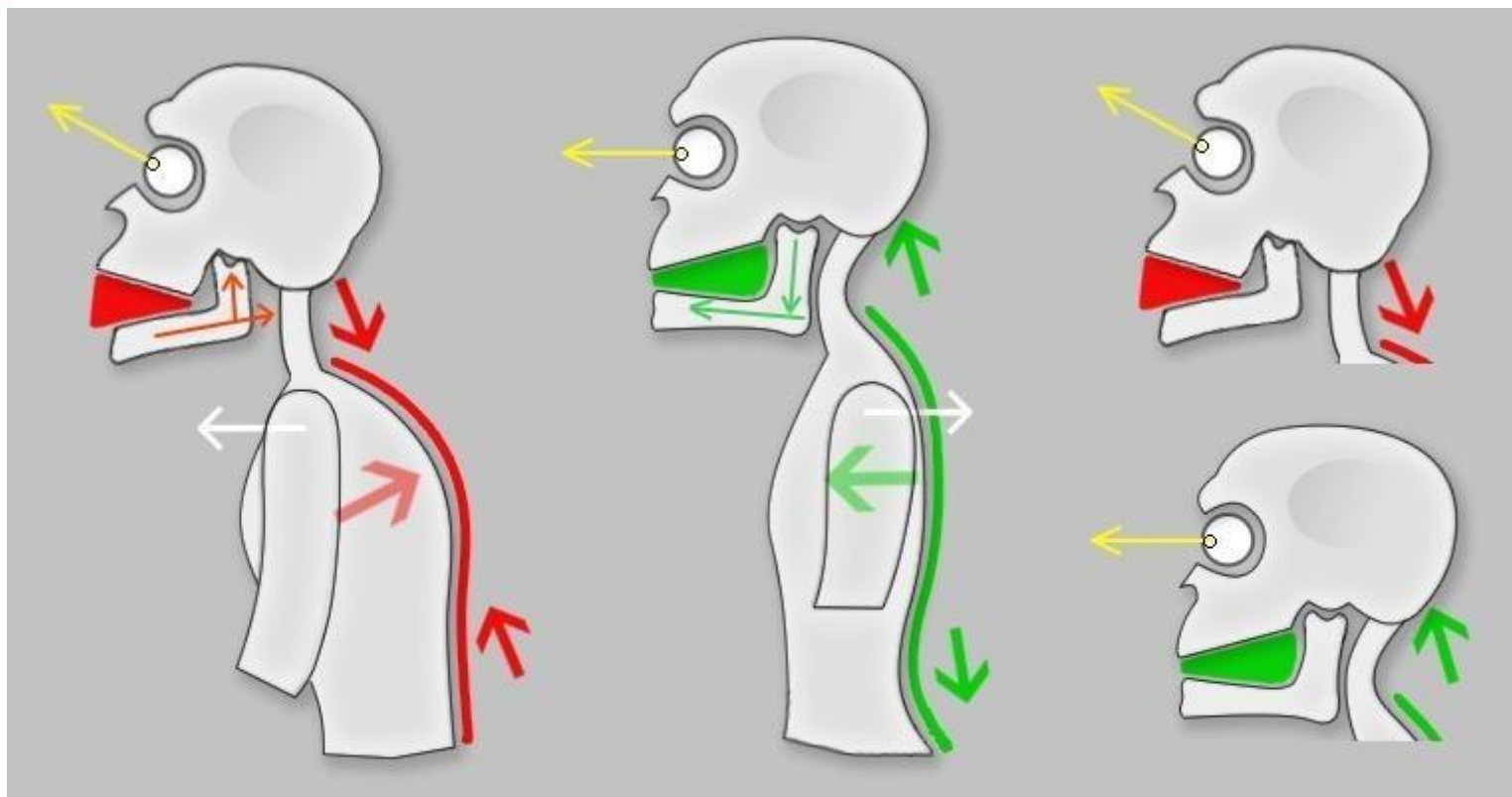
Dans le plan sagittal :

Il en résulte à l'inspire une prédominance des contacts molaires (plan sagittal)

Dans le plan frontal :

Les branches horizontales mandibulaires s'écartent. La partie post des maxillaires s'écartent d'ou : une prédominance de contact entre les cuspides palatines maxillaires et les cuspides vestibulaires mandibulaires.

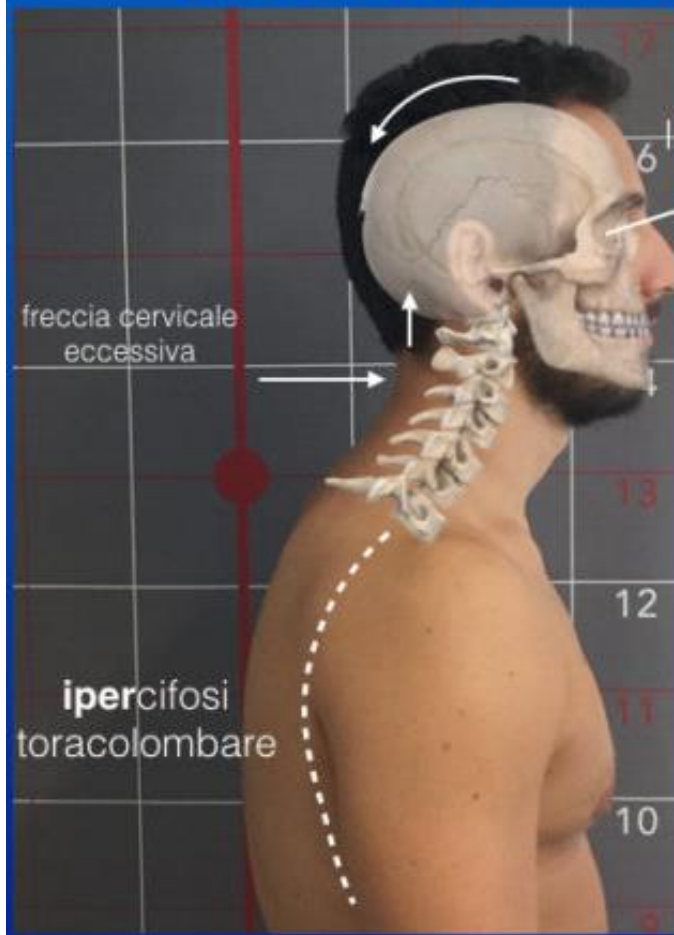Dans la phase d'Expiration les phénomènes inverses se produiront.



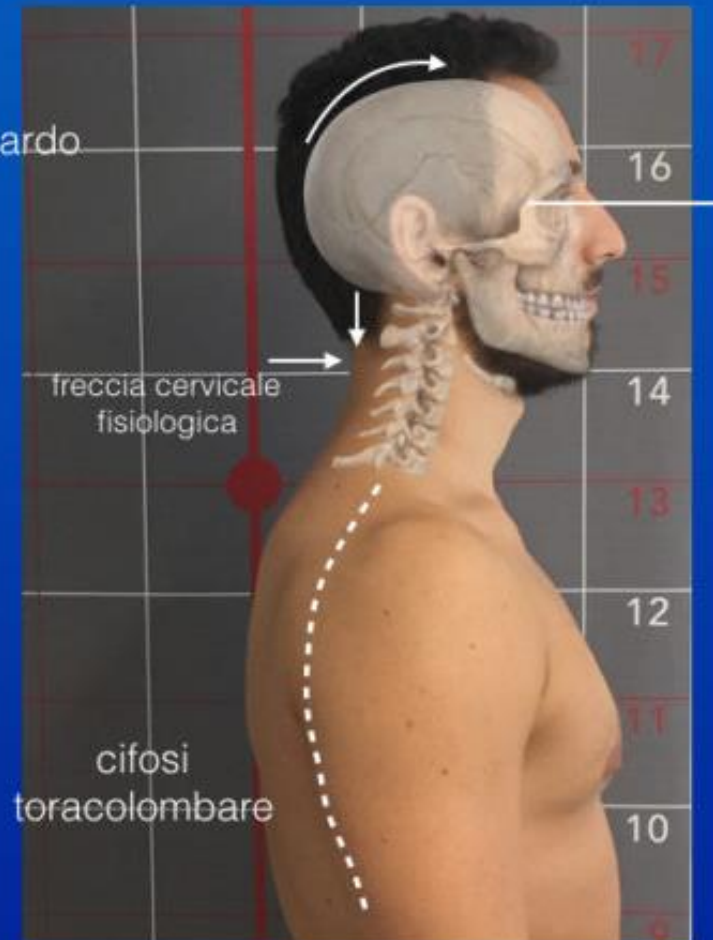**Postura da mancanza di spessore dentario (dimensione verticale) posteriore.**

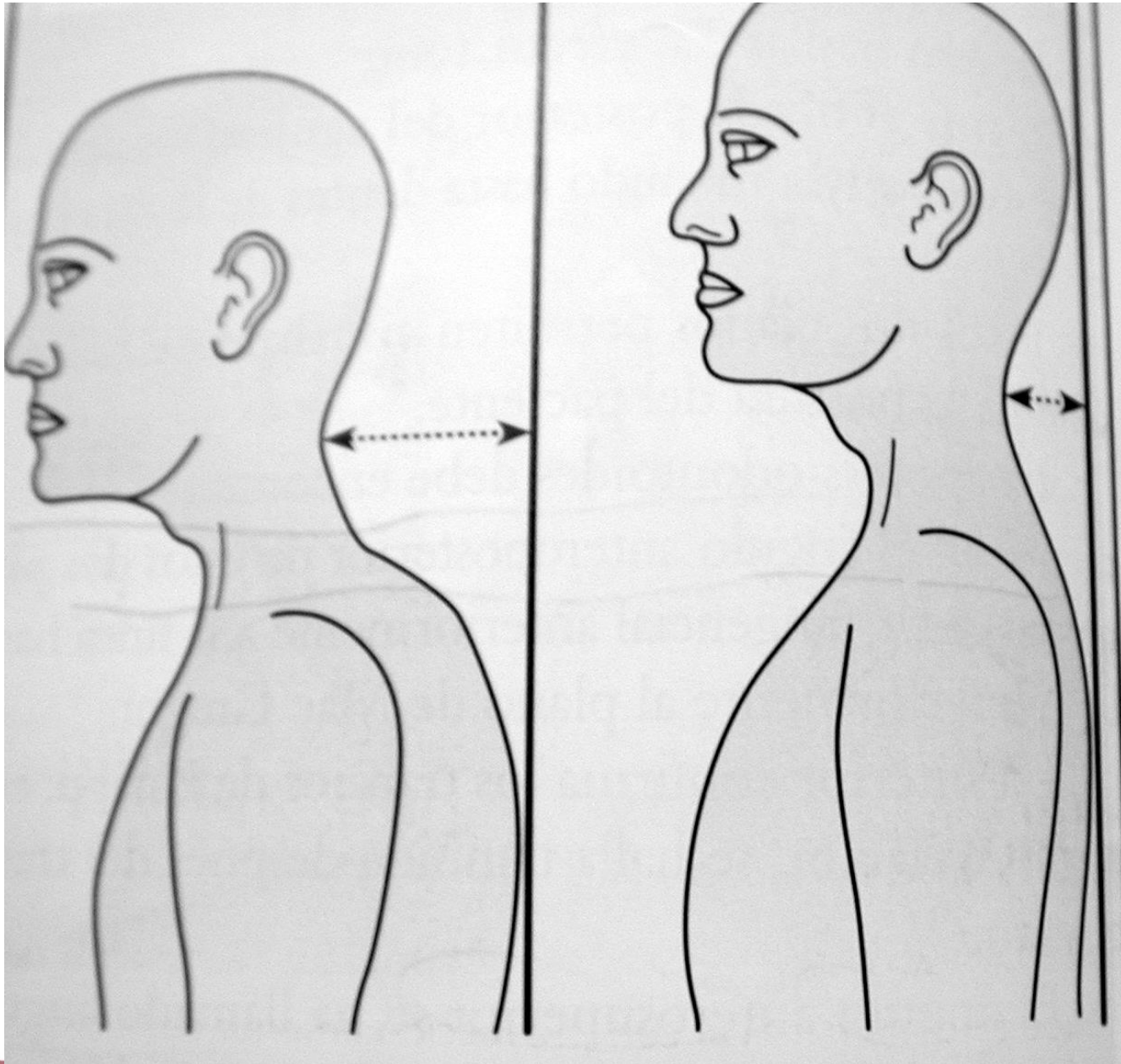
**Postura della persona Bilanciata, con dimensione verticale dentaria posteriore corretta.**

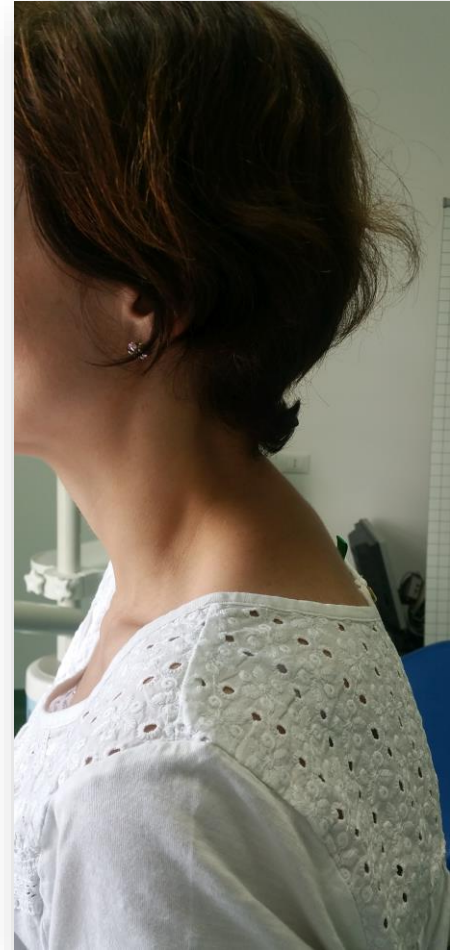
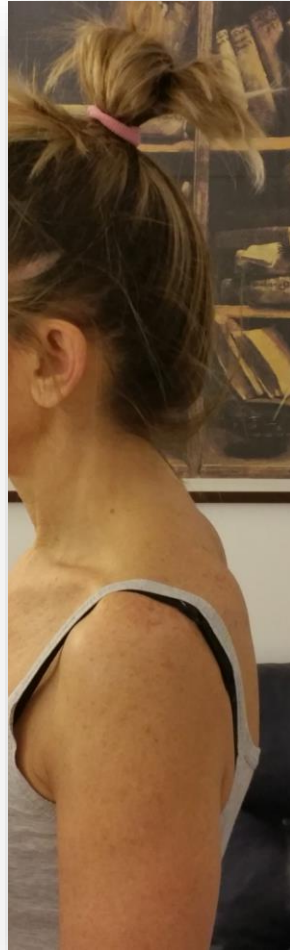## ext atl-occ.

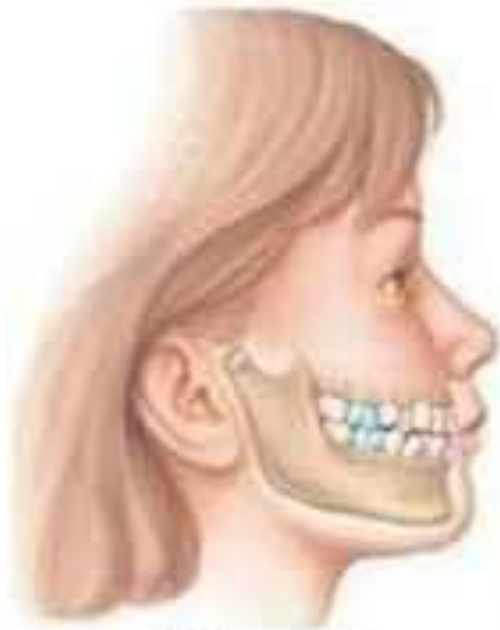

## flessione atl-occ.

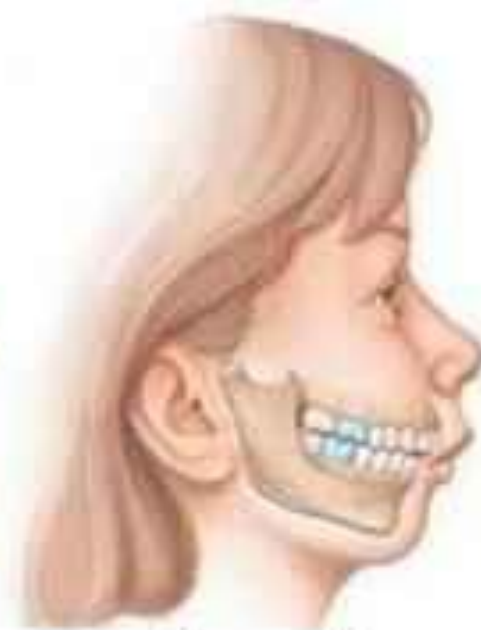




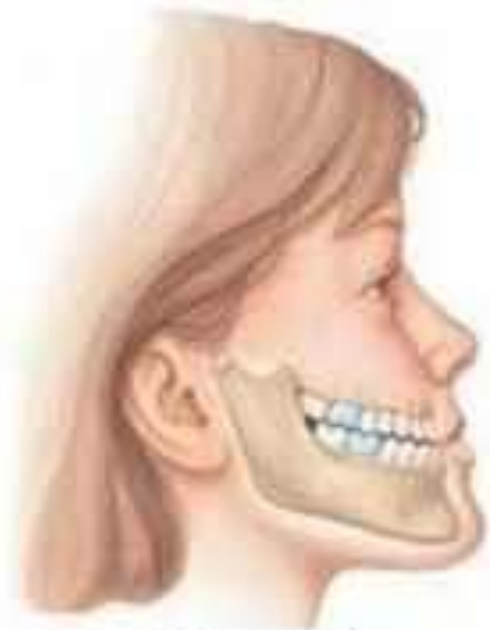


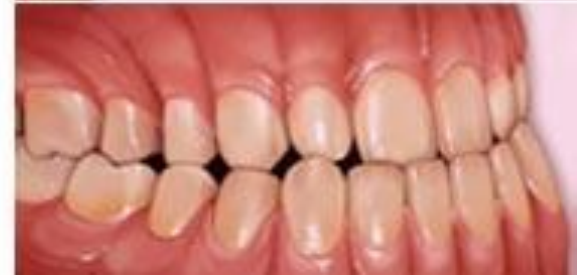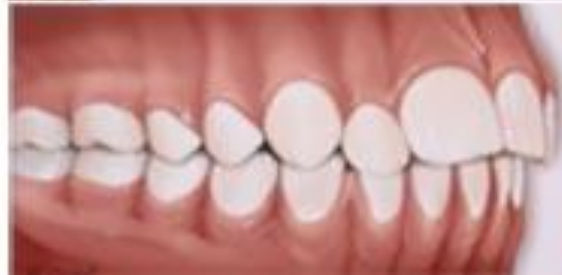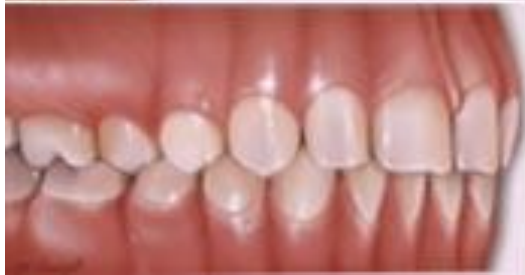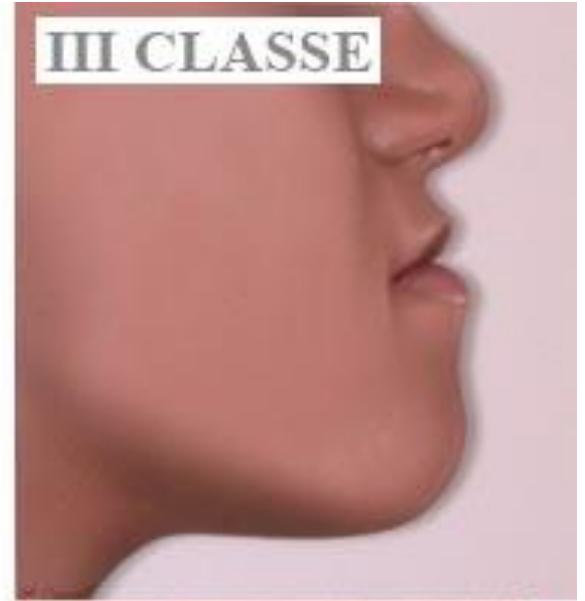
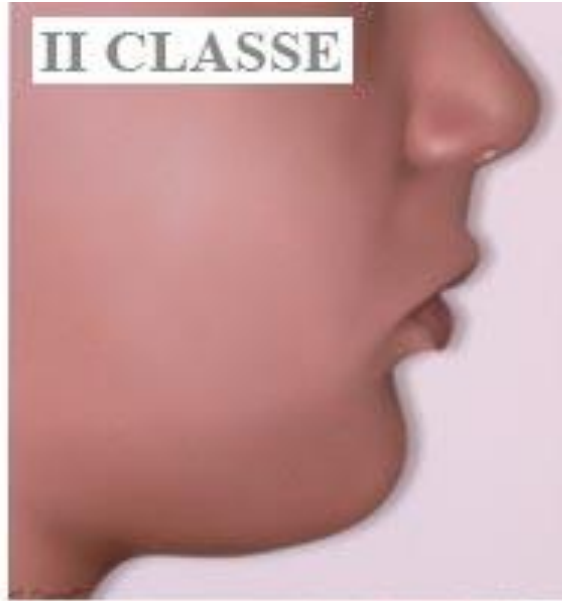
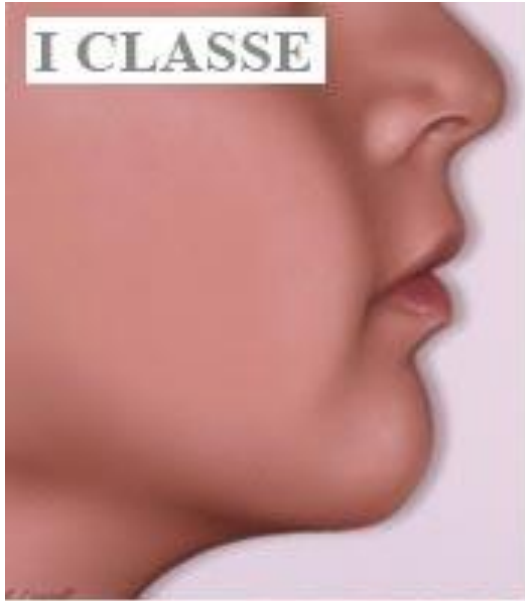
**Classe 1**



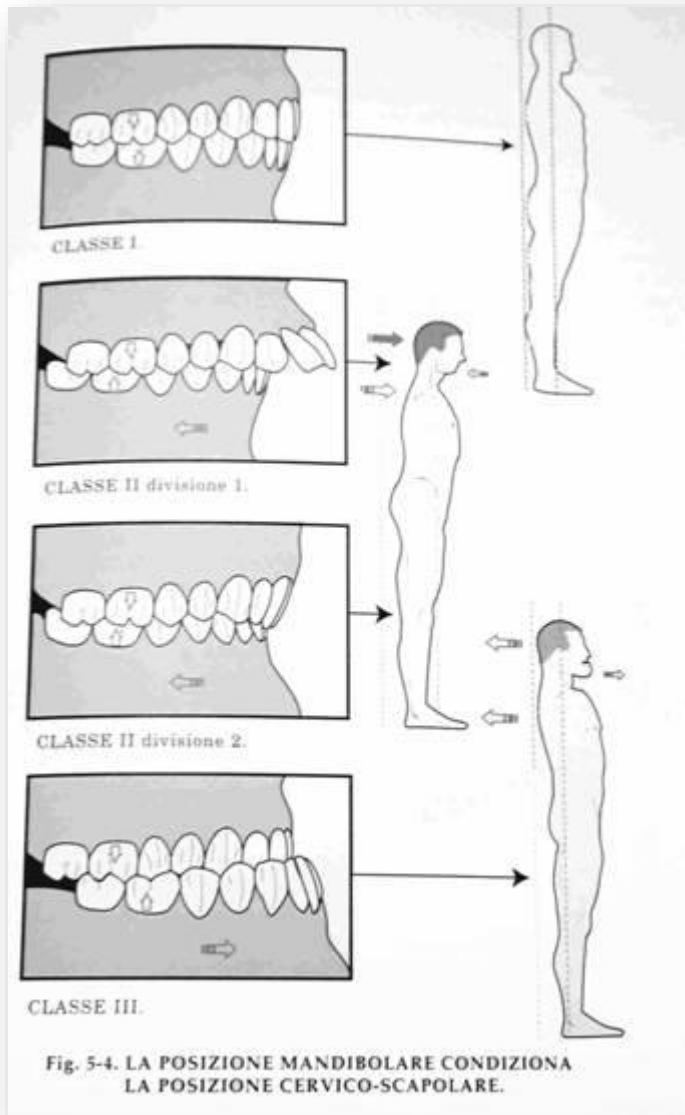
**Classe 2**



**Classe 3**



# LA MANDIBOLA È IL BILANCIERE DEL NOSTRO CORPO



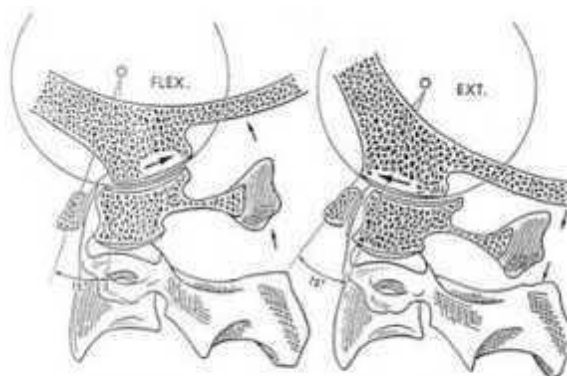


# Postura iniziale



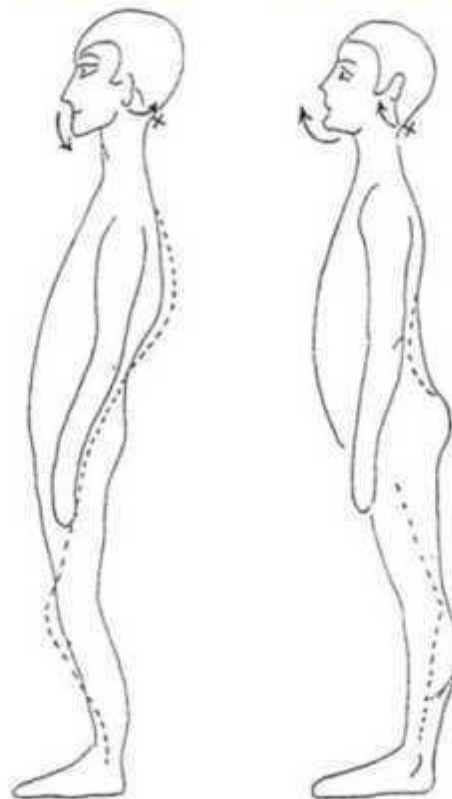
# Postura dopo applicazione di Frankel II

RELAZIONE TRA  
C0-C1  
E LA  
POSTURA  
MANDIBOLARE



III classe

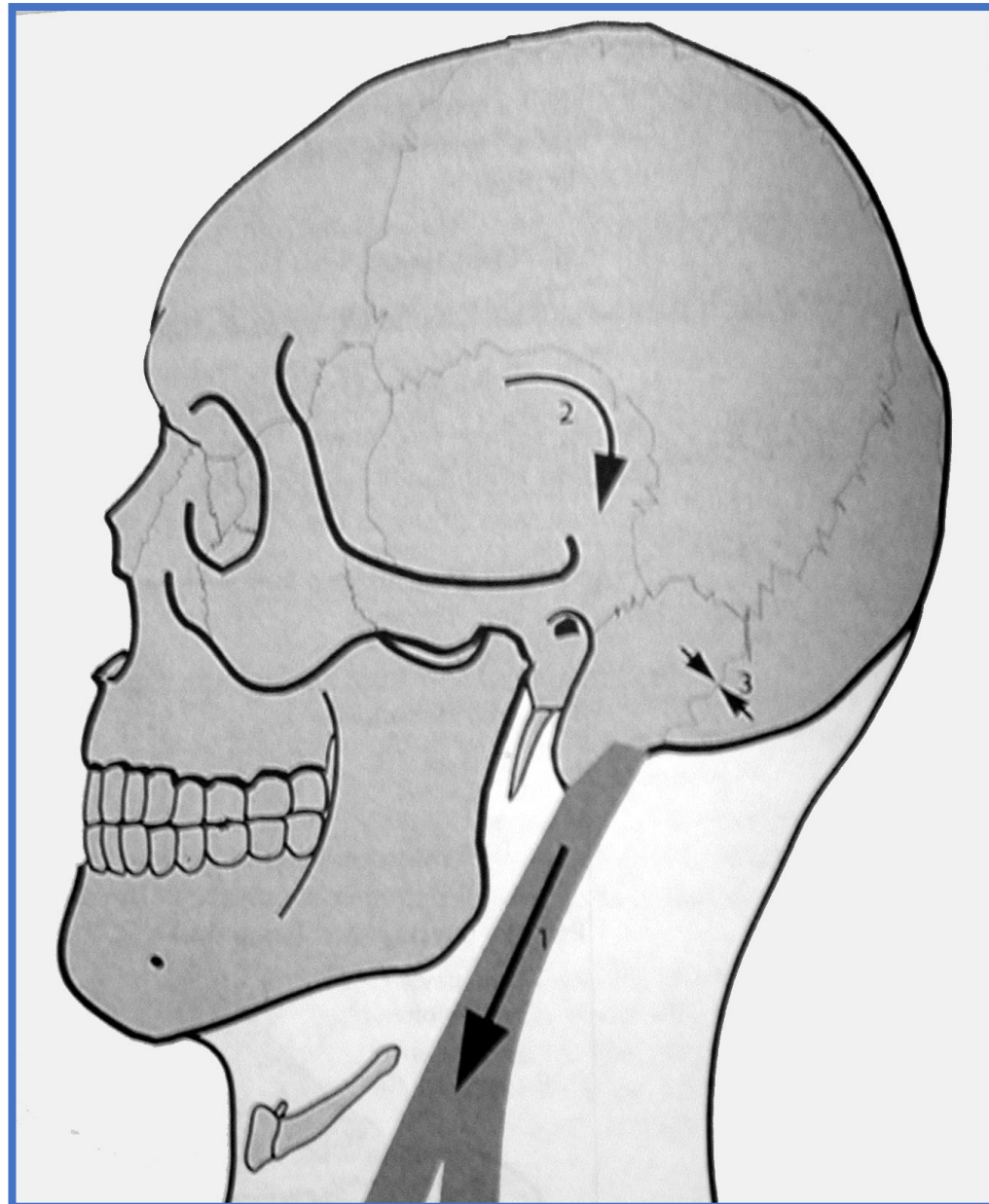
II classe



# EFFETTI DELL'IPERTONO DEI MUSCOLI MASTICATORI

## Effetti della ipertonia dello SCOM:

- Rotazione interna del temporale
- compressione della sutura OM..

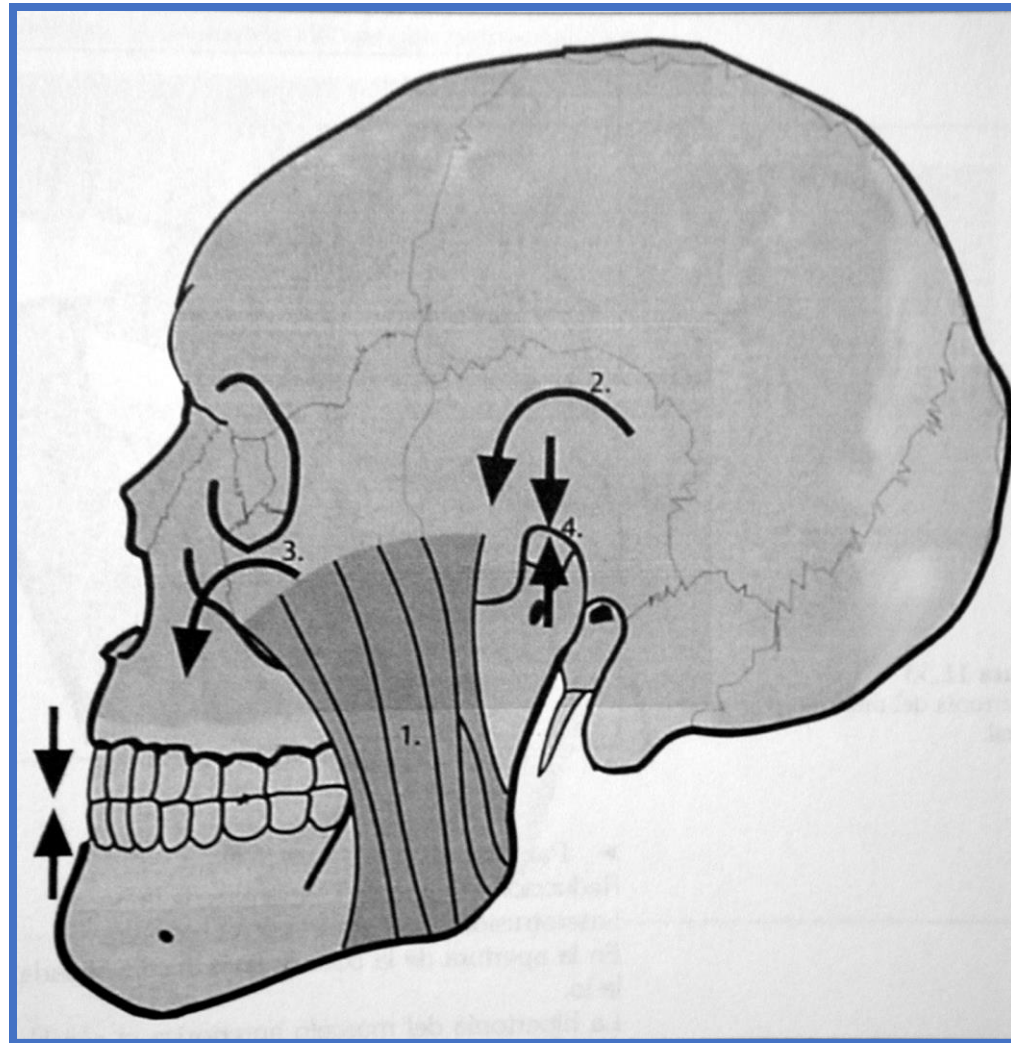


## Effetti dell'ipertono del massetere:

zigomatico in RE

temporale in rot  
anteriore

ATM compressa

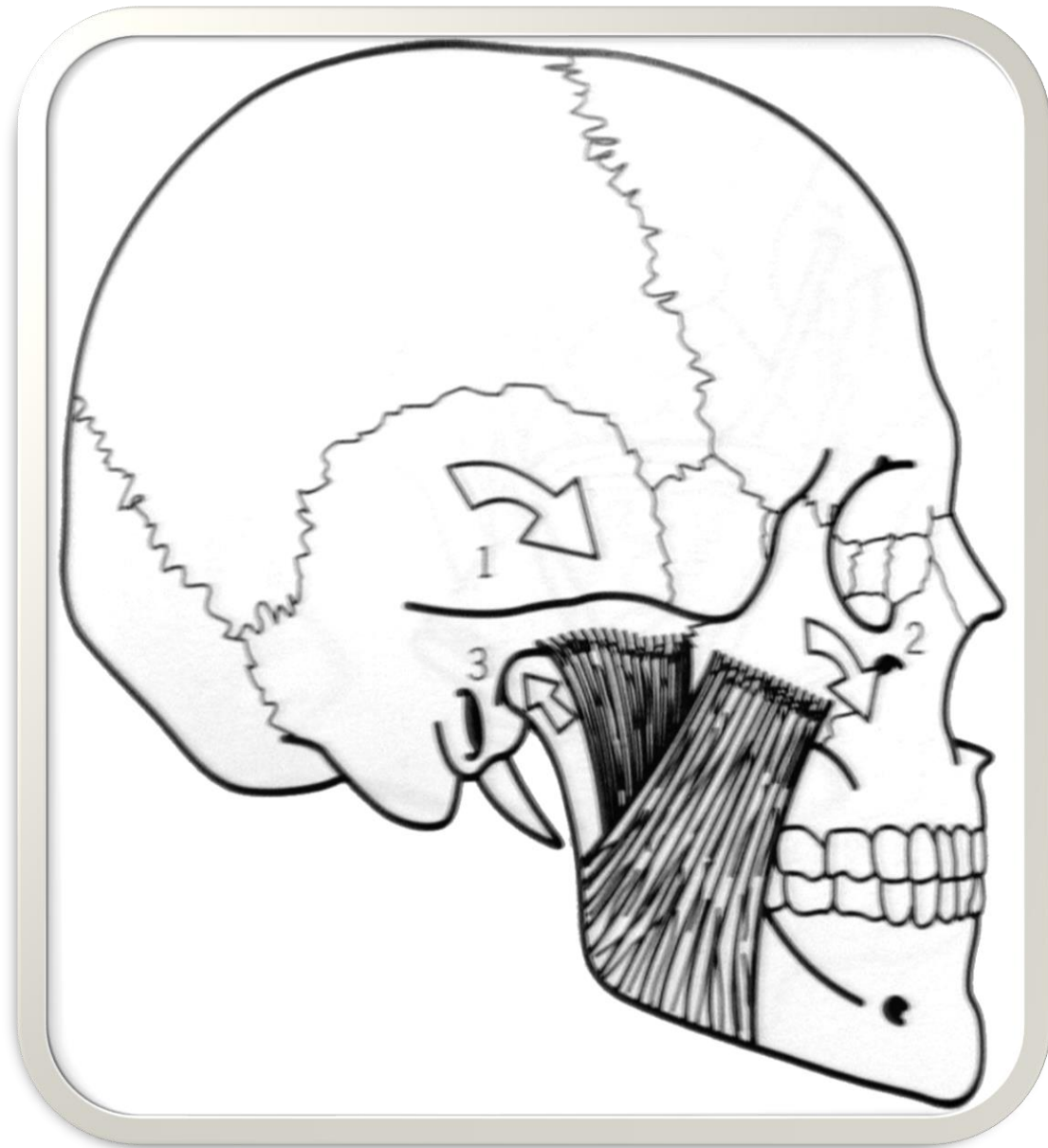

**SPASMO DEL  
MASSETERE**

**FLESSIONE DEL  
TEMPORALE**

**MALARE IN RE**

**CONDILO  
POSTERIORIZZATO**



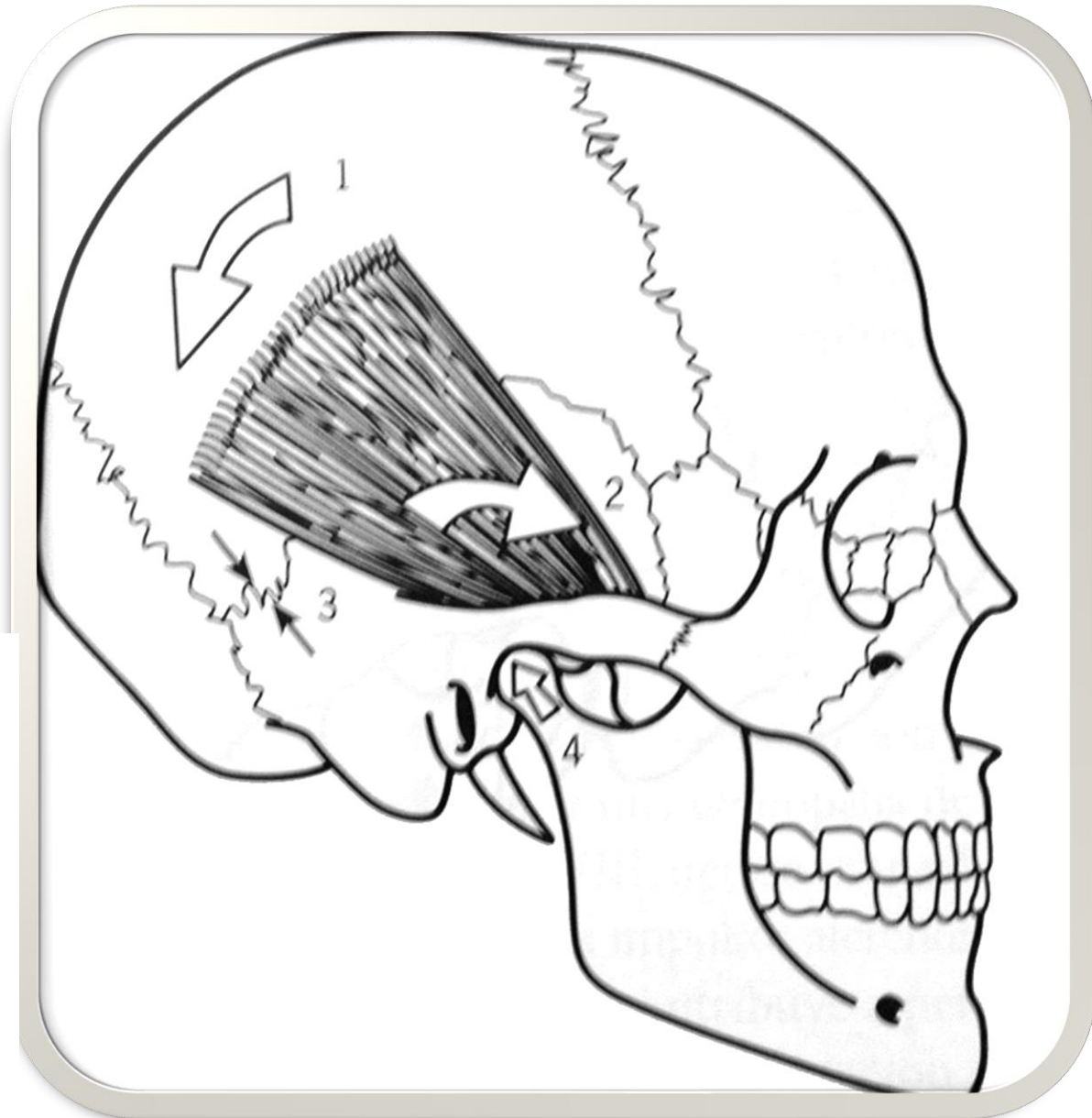
**SPASMO DEL  
TEMPORALE  
POSTERIORE**

**DISFUNZIONE  
PARIETALE**

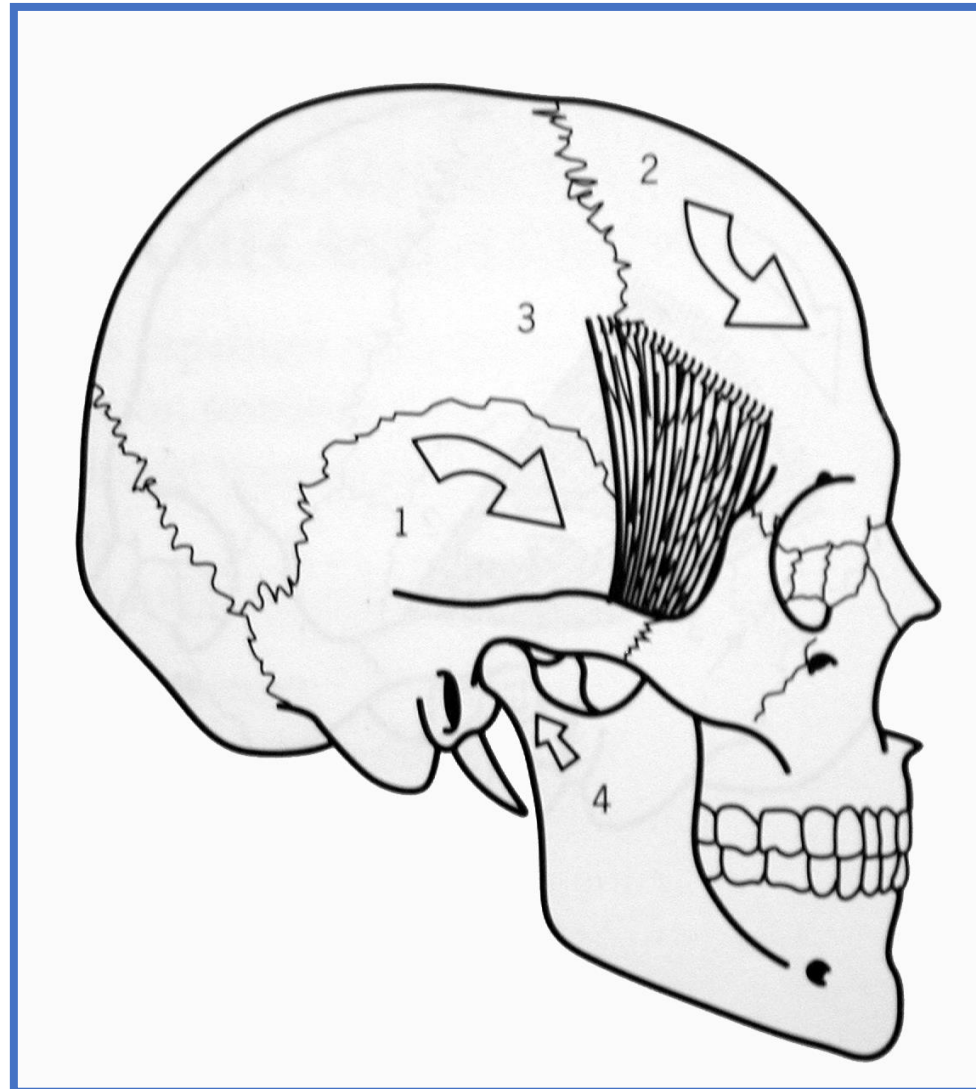
**TEMPORALE IN RE**

**ASTERION DOLENTE**

**CONDILO  
POSTERIORE**

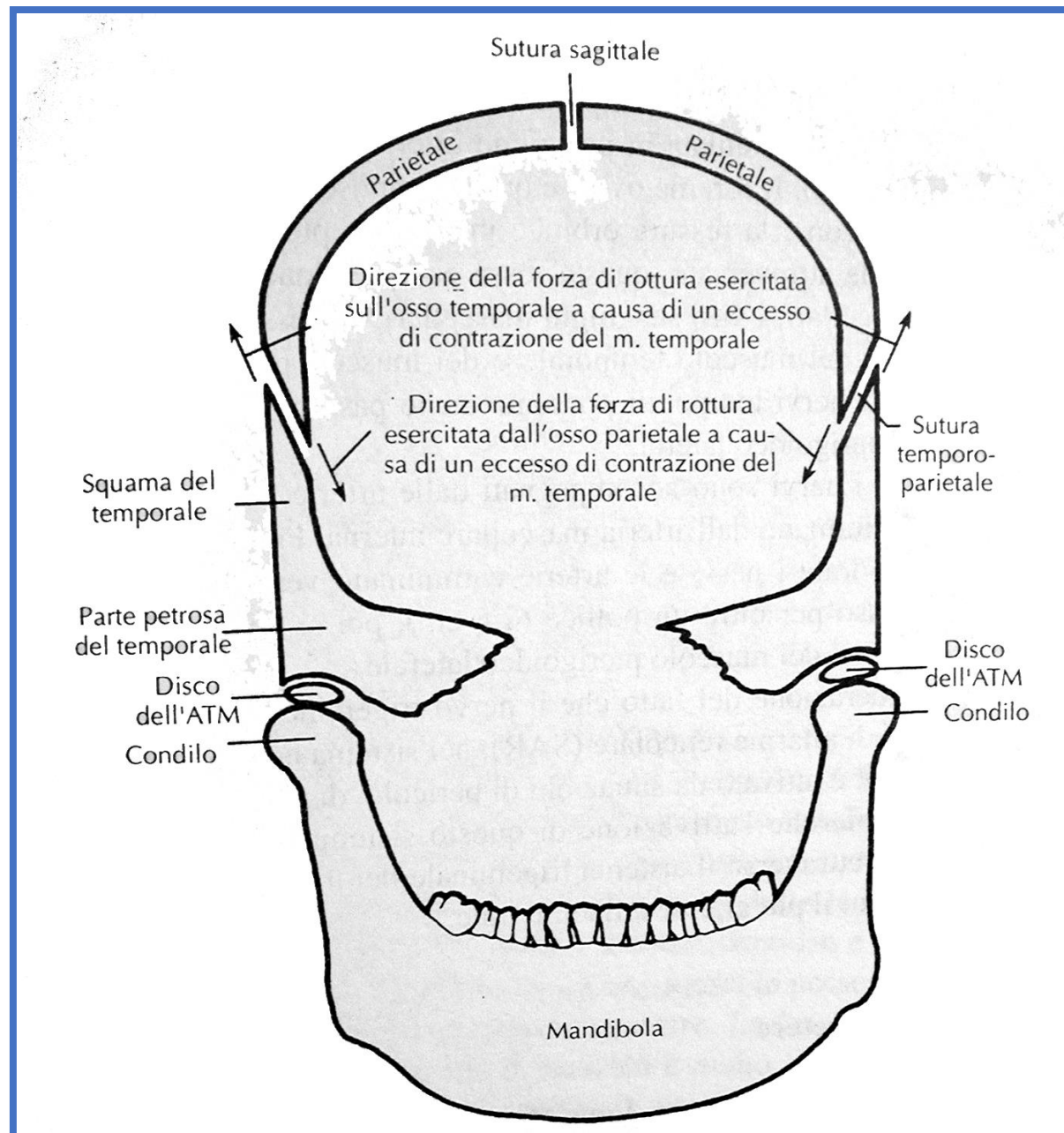


**TEMPORALE IN RE**  
**FRONTALE IN RI**  
**BLOCCO ANGOLO**  
**ANT DEL PARIETALE**  
**COMPRESSIONE ATM**



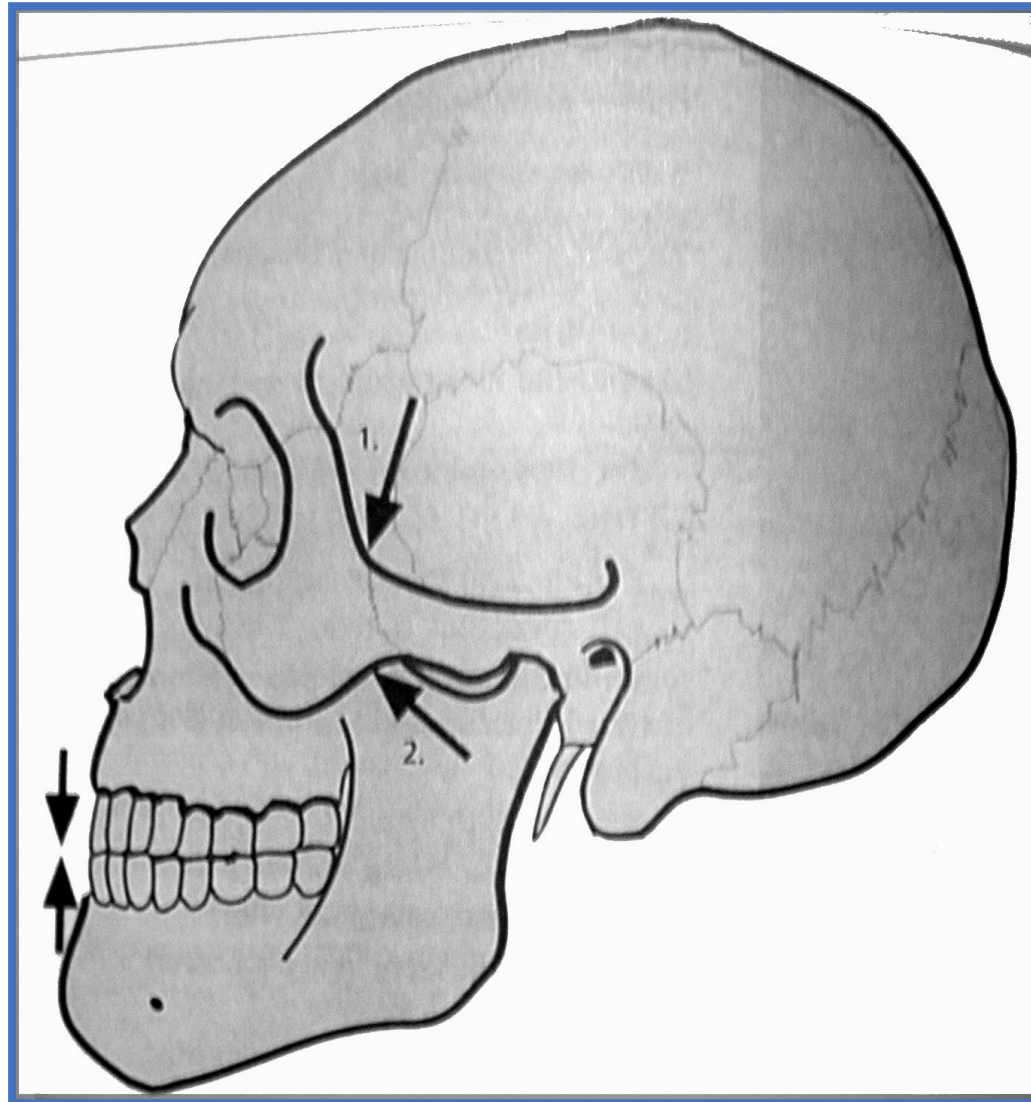
**SPASMO DEL TEMPORALE ANTERIORE**

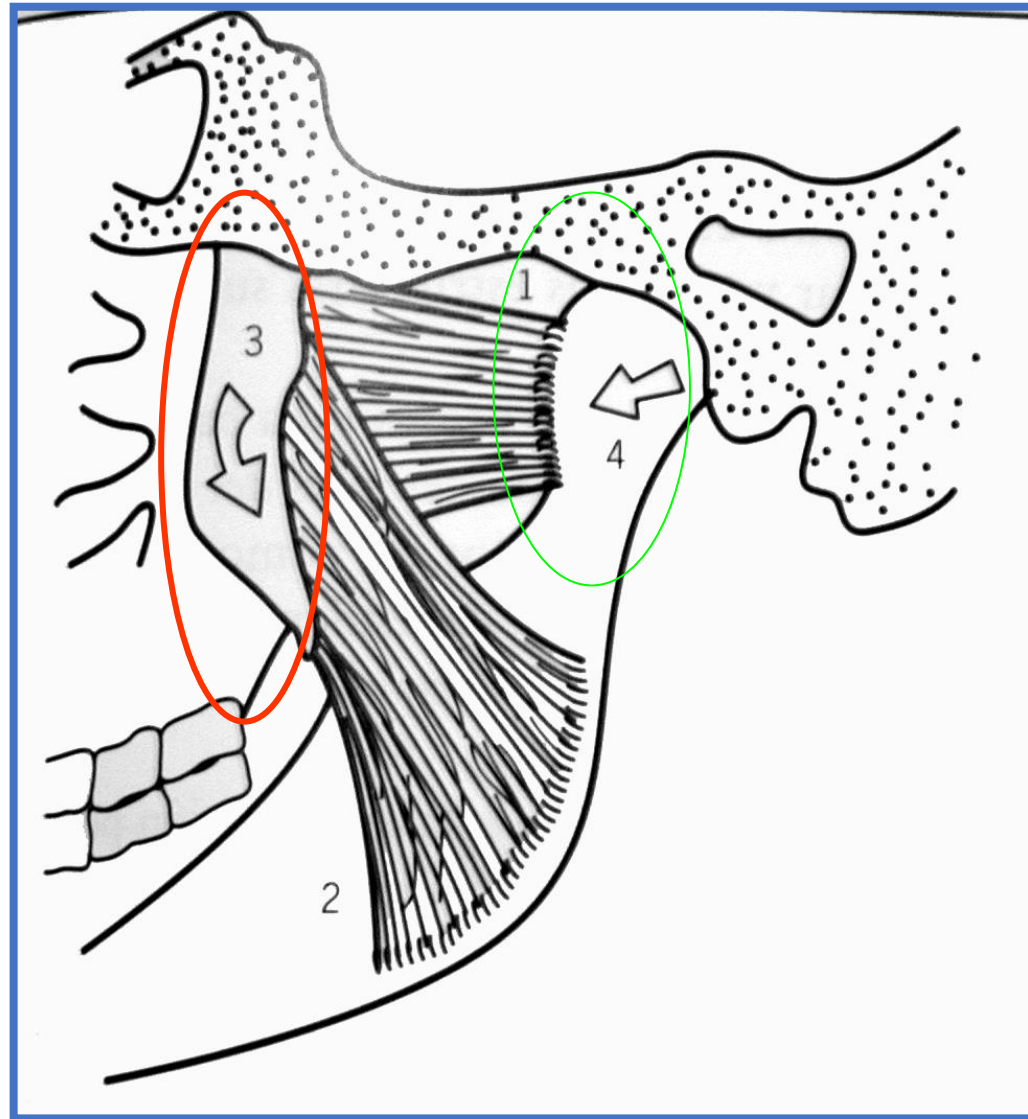
# SPASMO DEL TEMPORALE



## Effetti della ipertonia dello pteroideo interno:

- condilo alto  
e avanti
- pterigoidi  
indietro

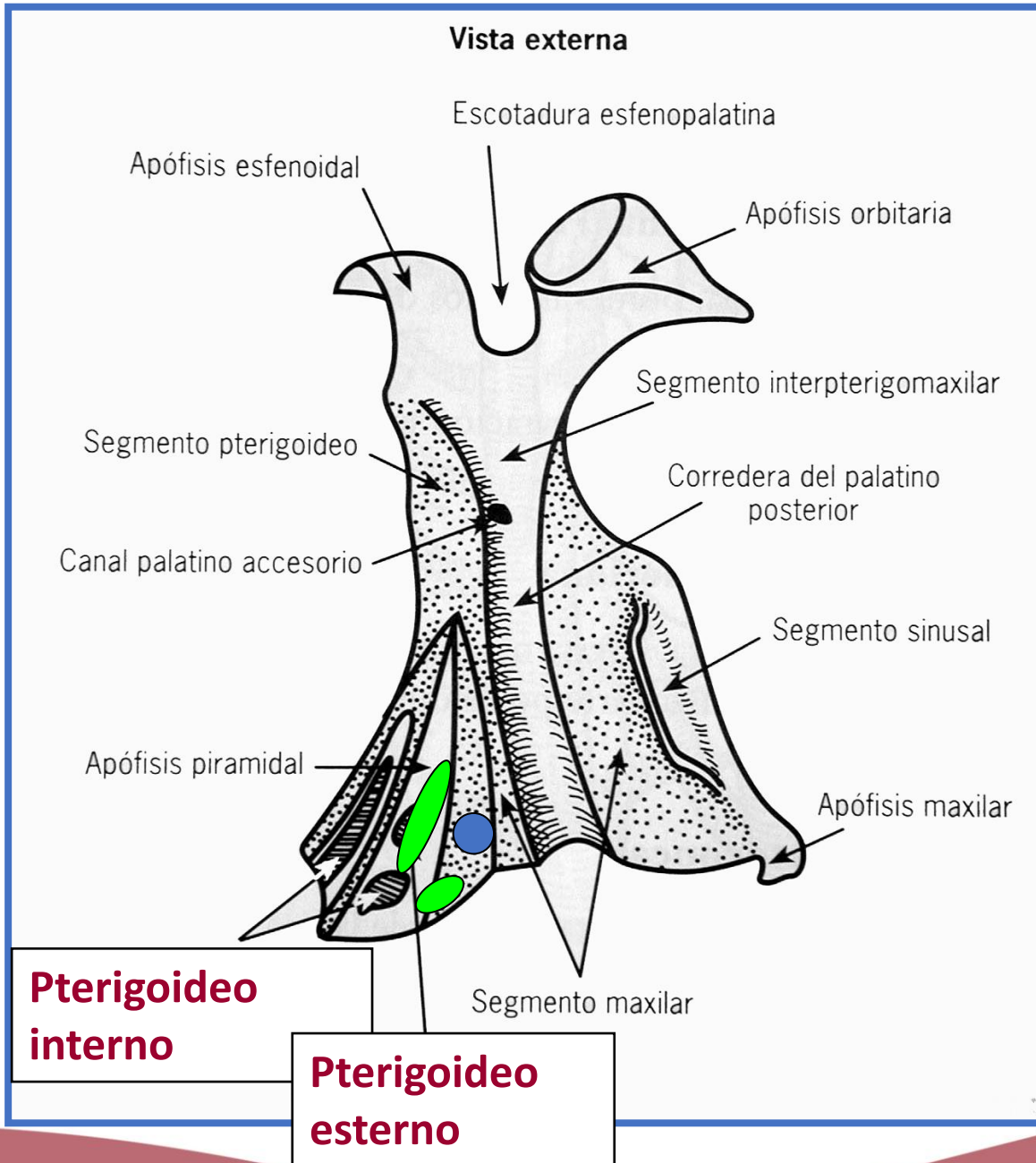


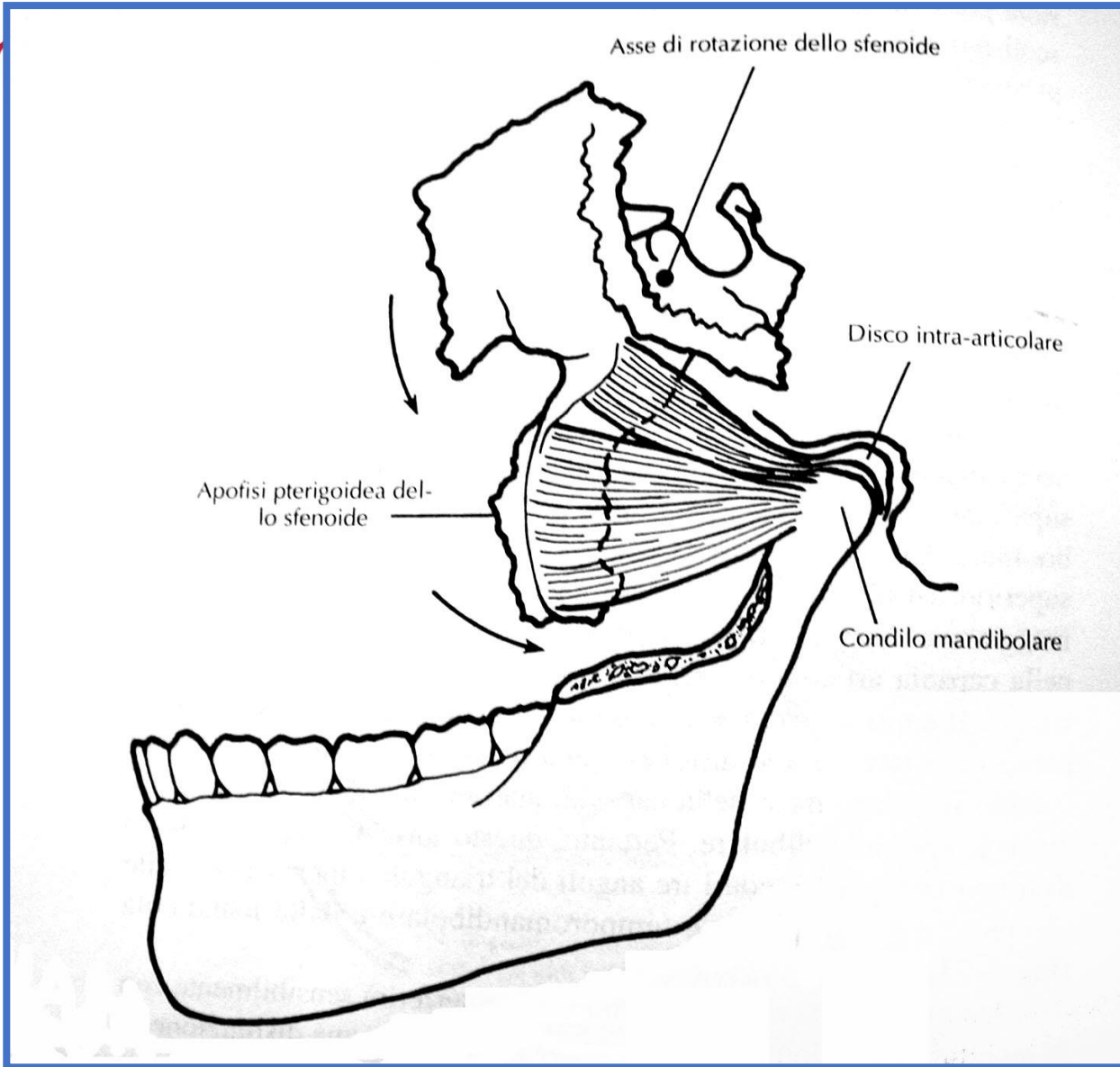


**Apofisi  
ptericoidi in  
flessione**

**Anteriorizzazione  
di condilo e  
menisco**

**Effetto dello spasmo degli pterigoidei**





INTRODUZIONE

TEST DEL CRANIO BOCCA APERTA E CHIUSA

MODALITÀ DI APERTURA DELLA BOCCA

CONTROLLO ALLINEAMENTO DENTI

DEGLUTIZIONE



INTRODUZIONE



TEST DEL CRANIO BOCCA APERTA E CHIUSA



MODALITÀ DI APERTURA DELLA BOCCA

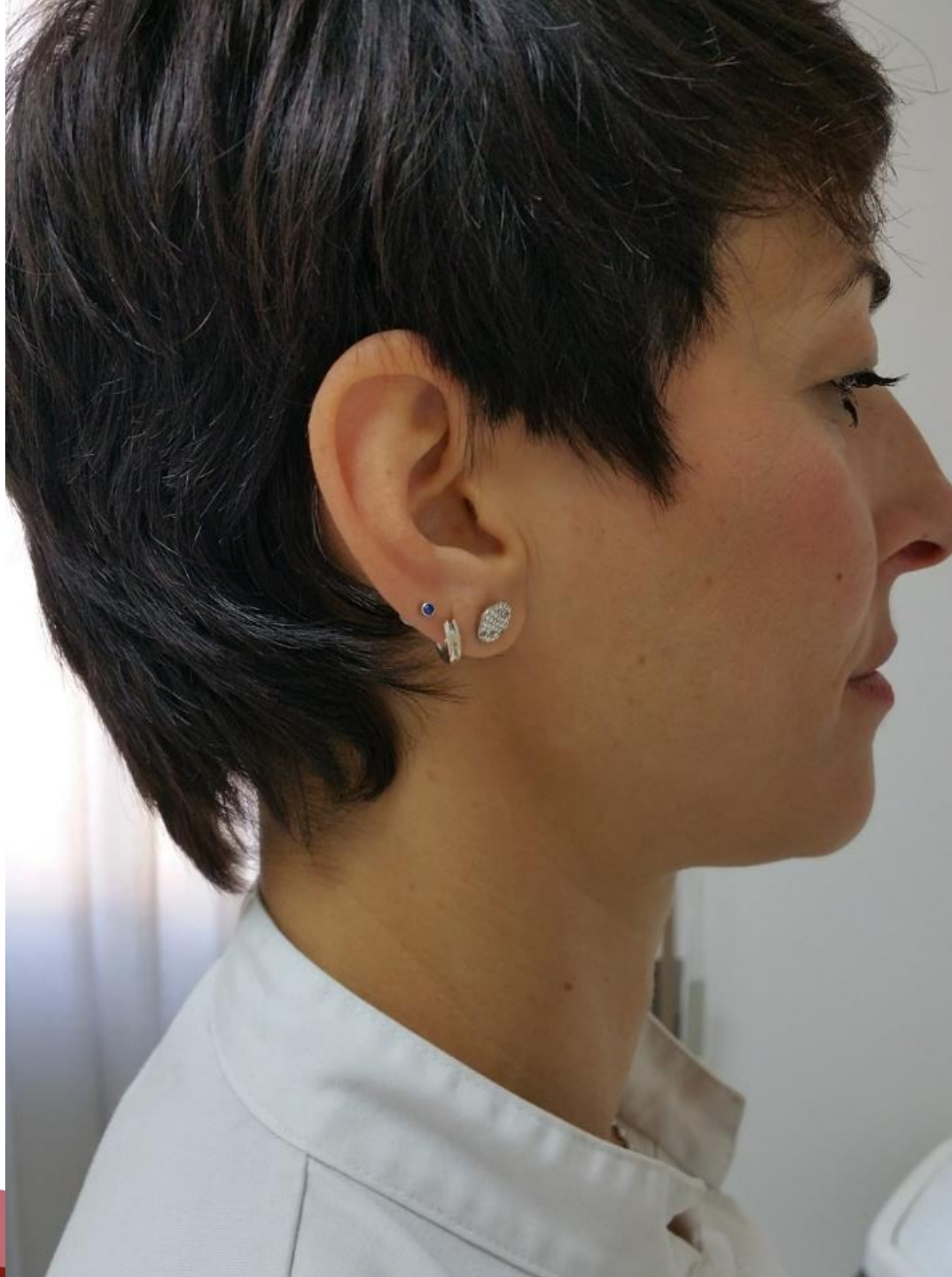

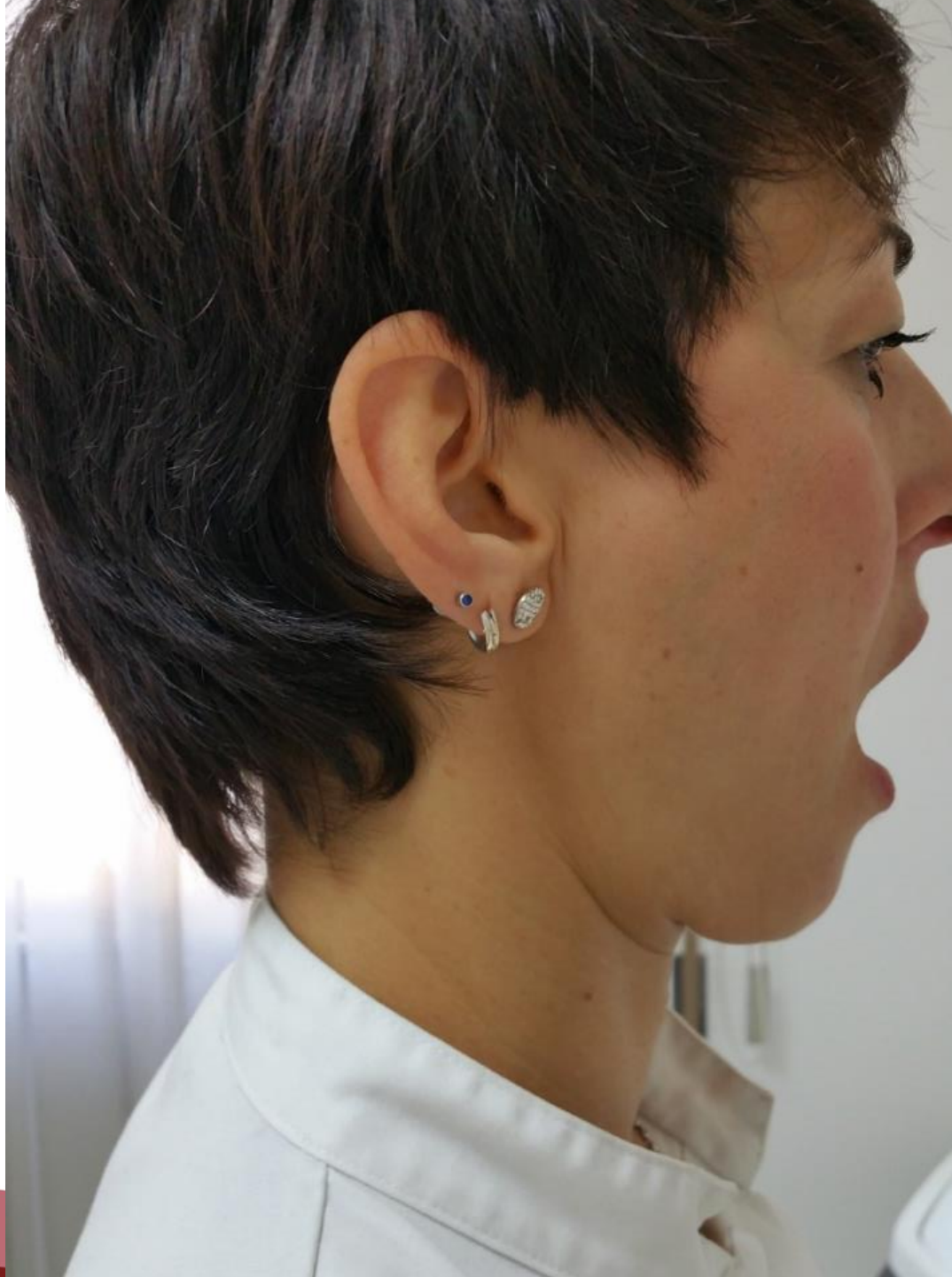CONTROLLO ALLINEAMENTO DENTI

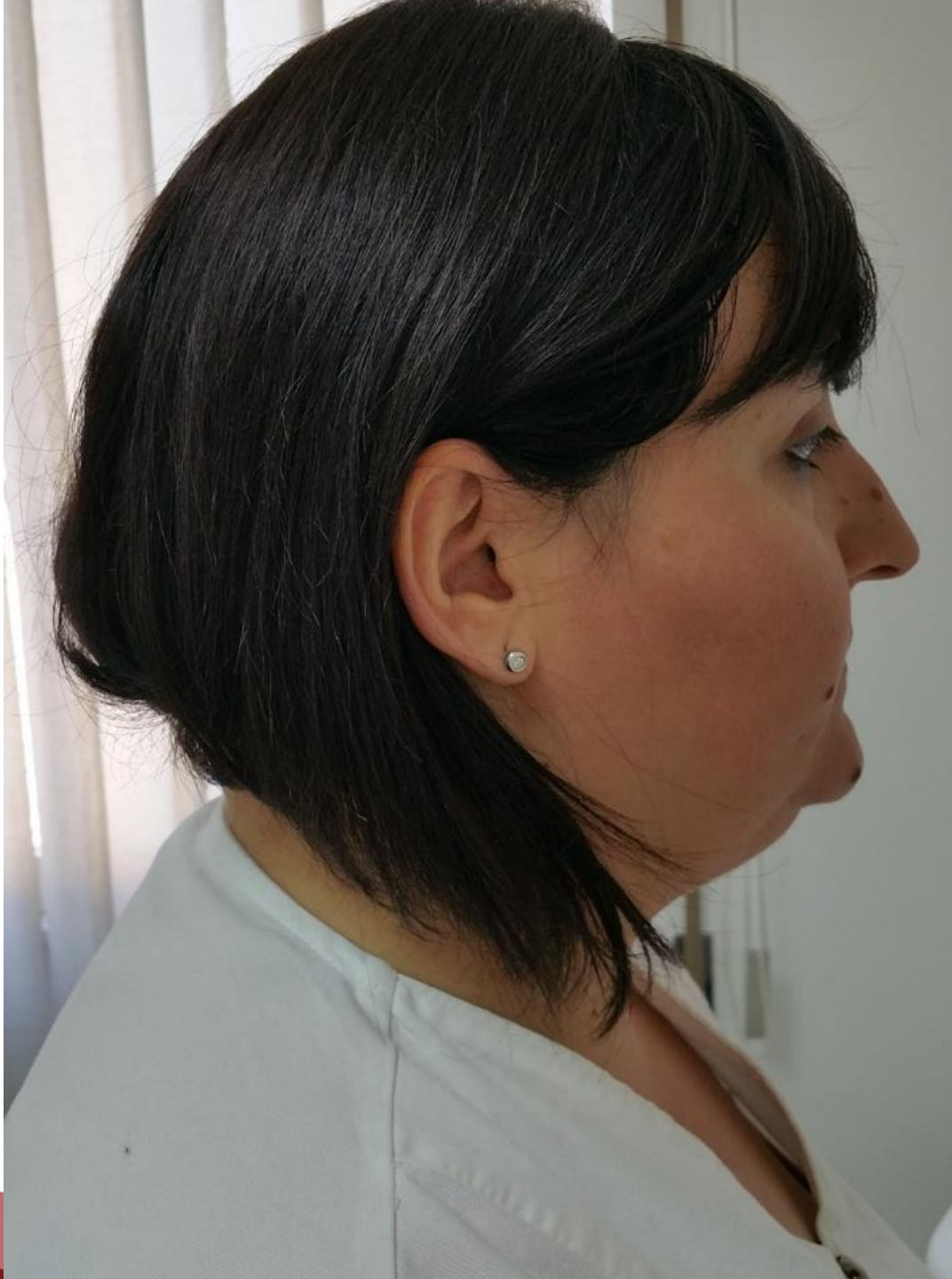

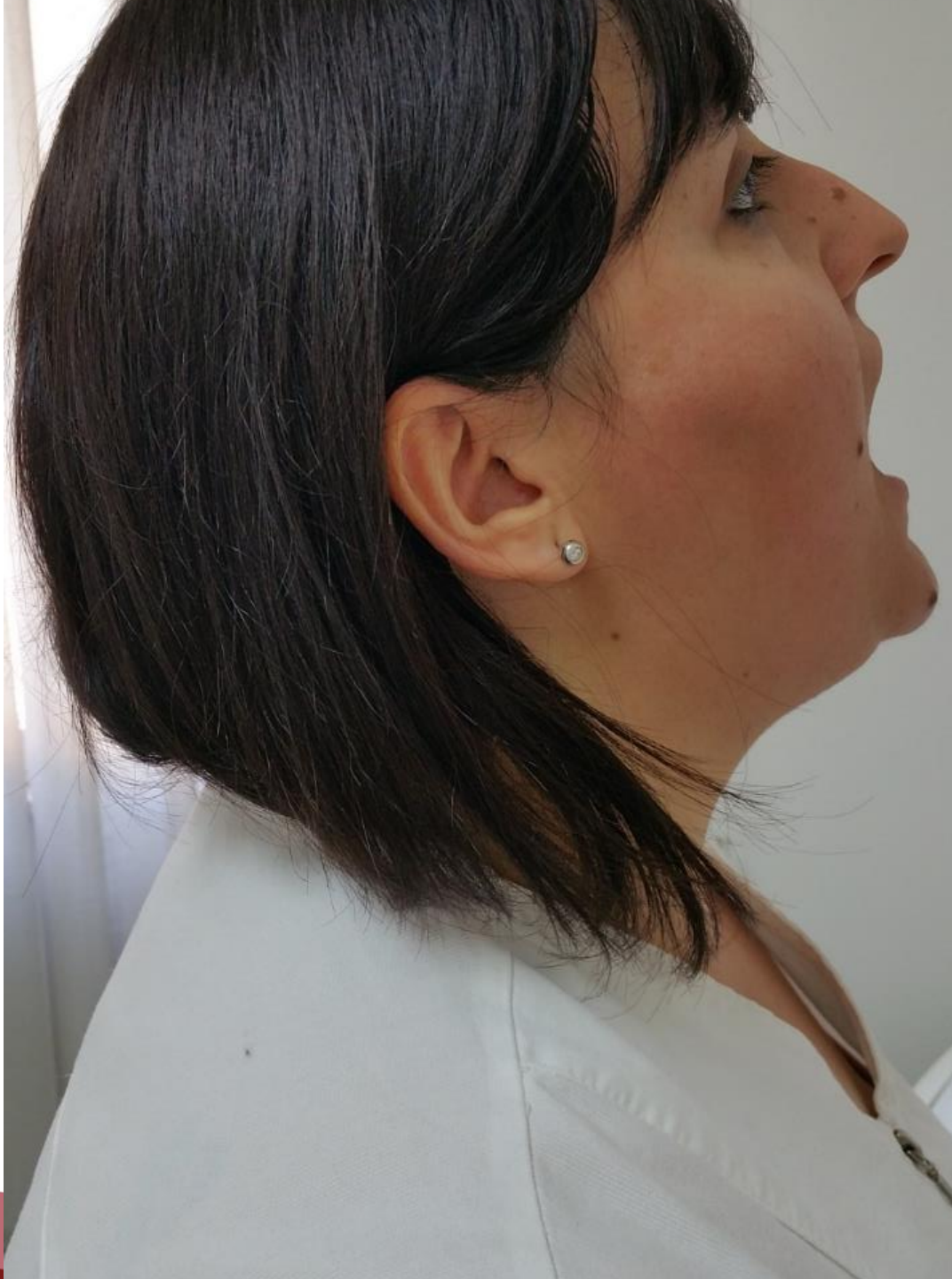DEGLUTIZIONE

# Verifica apertura massima della bocca



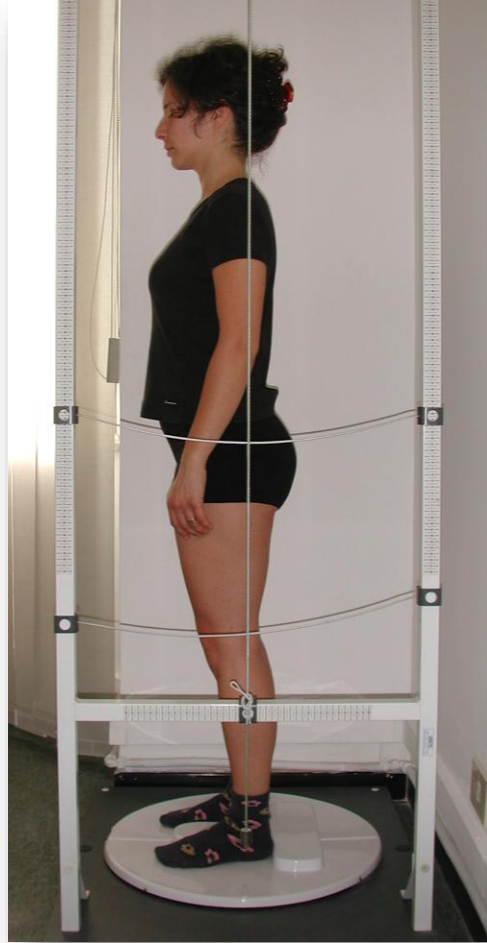


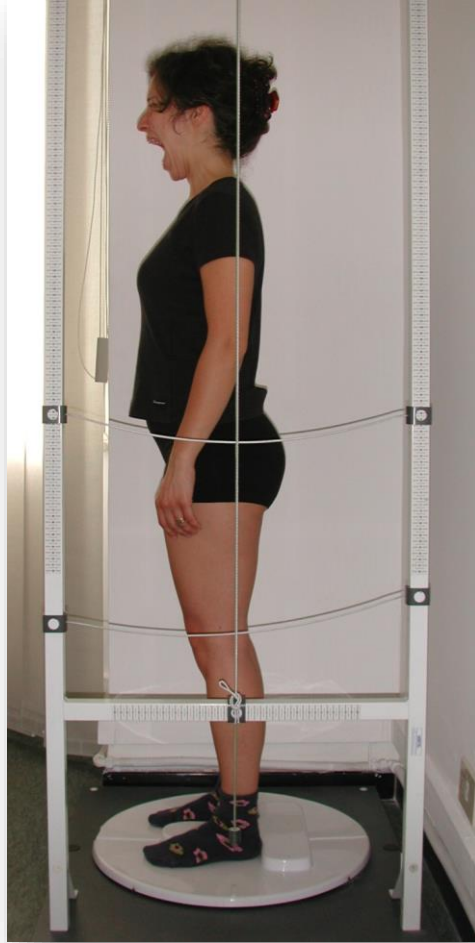





# Test Di Apertura Massima







# Apertura massima



# APERTURA E ATM

INTRODUZIONE



TEST DEL CRANIO BOCCA APERTA E CHIUSA



MODALITÀ DI APERTURA DELLA BOCCA

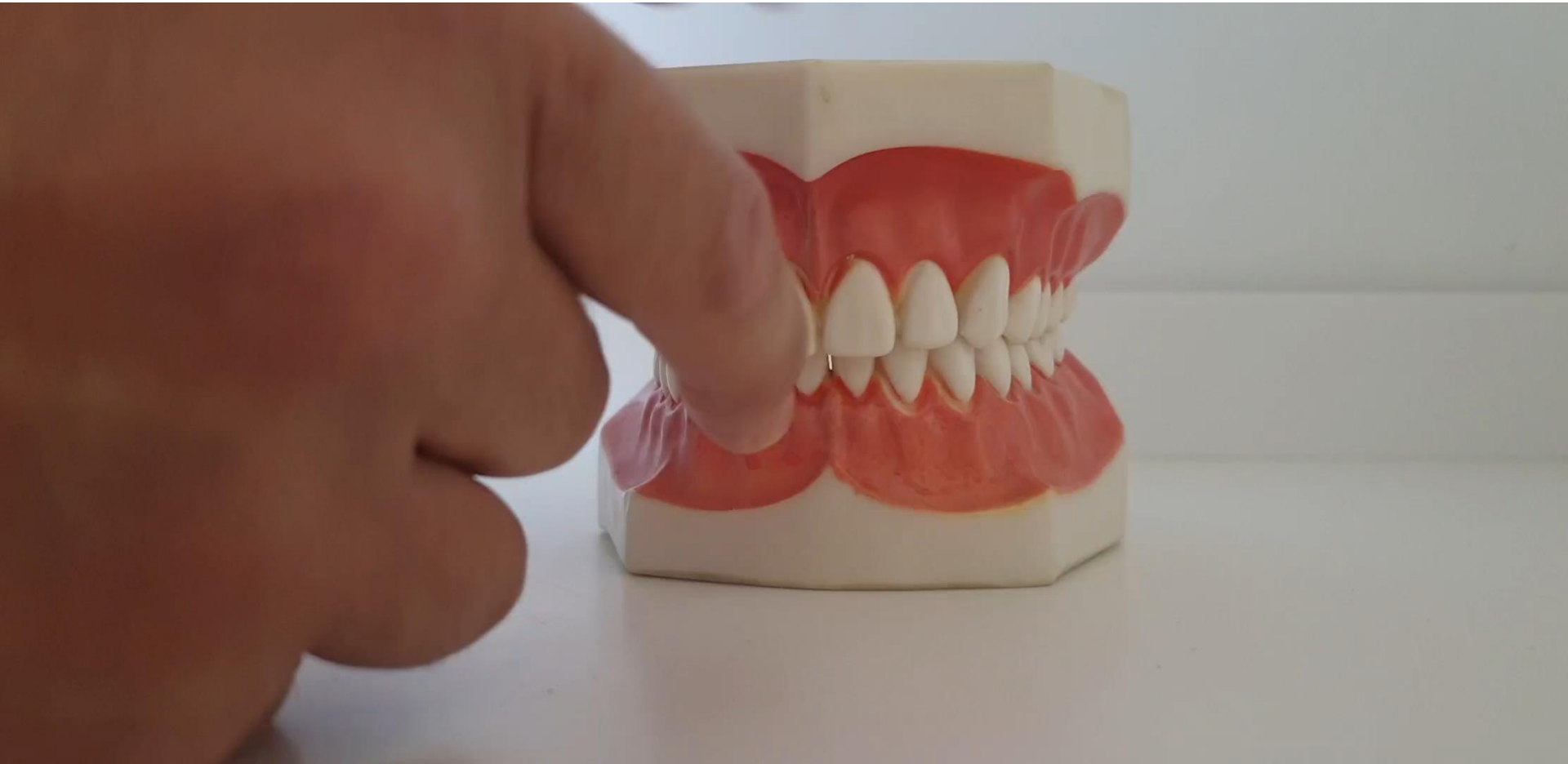


CONTROLLO ALLINEAMENTO DENTI

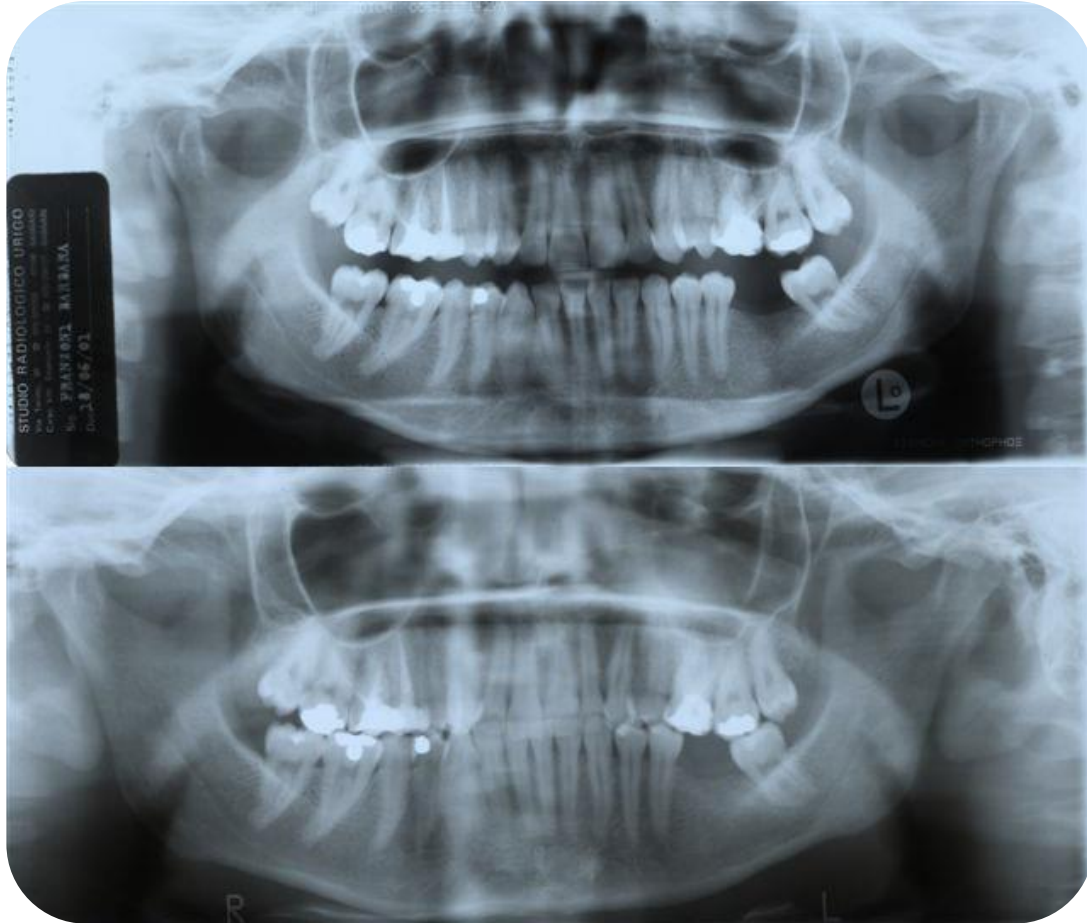


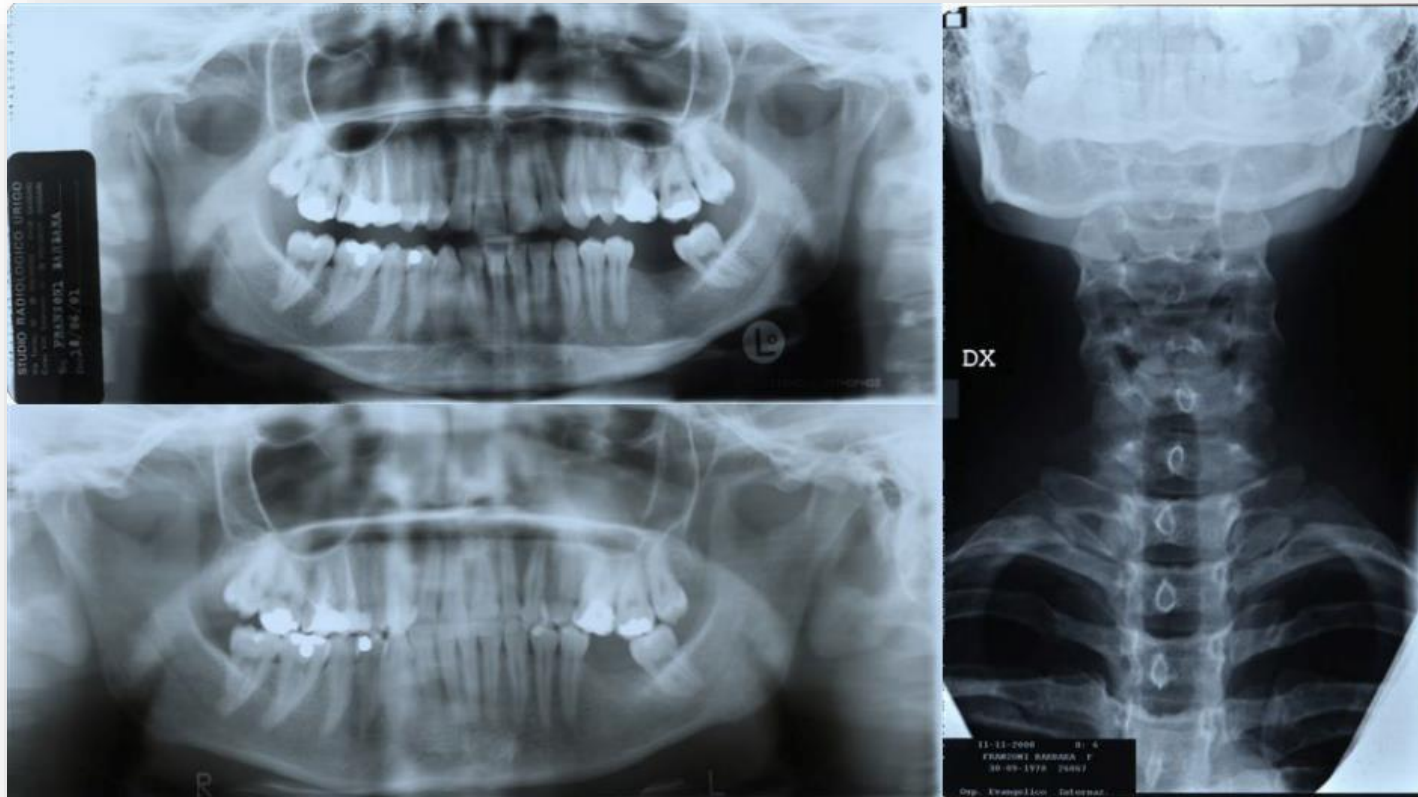
DEGLUTIZIONE

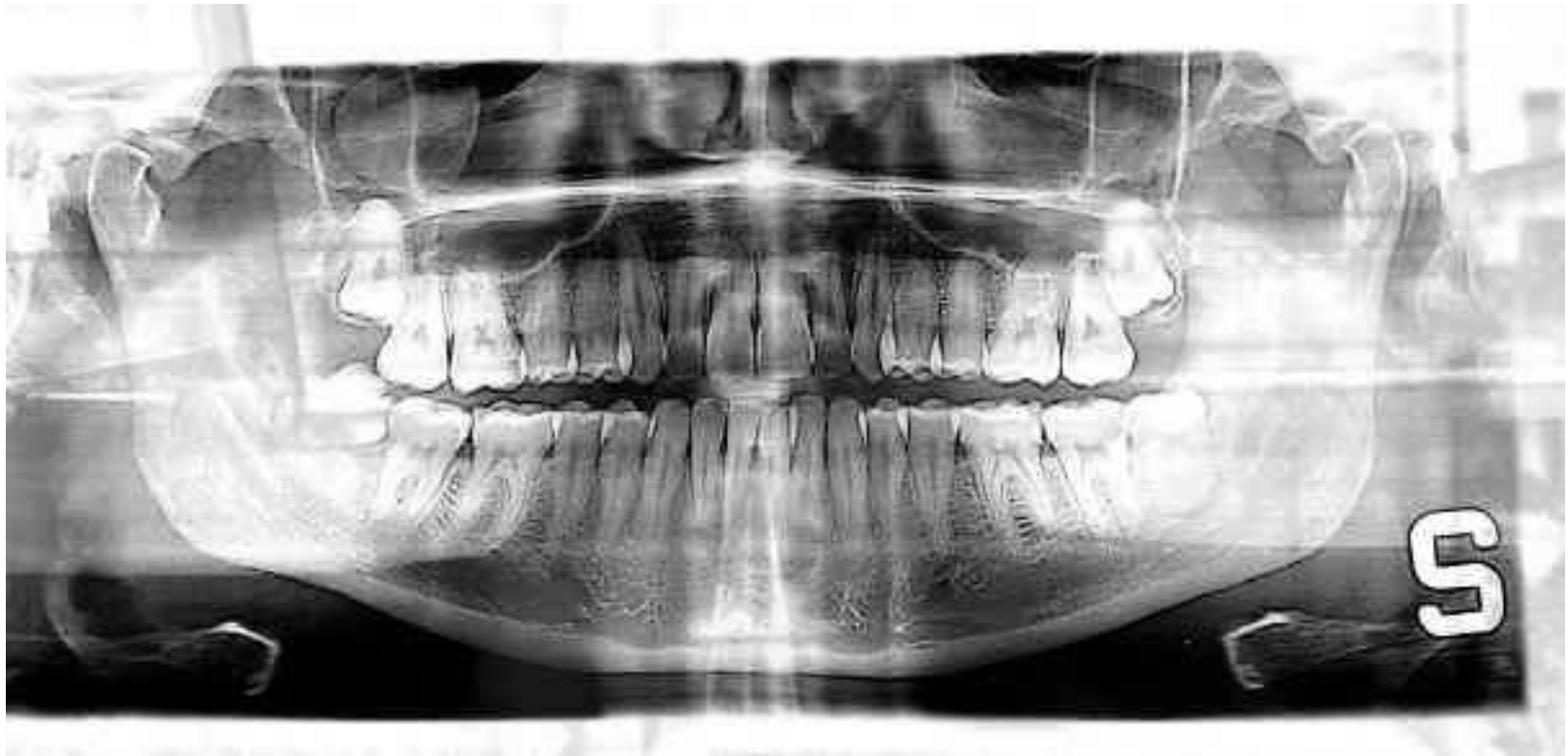# Test e trattamento dei denti «neurologici»



# INTERFERENZA DEI DENTI DEL GIUDIZIO



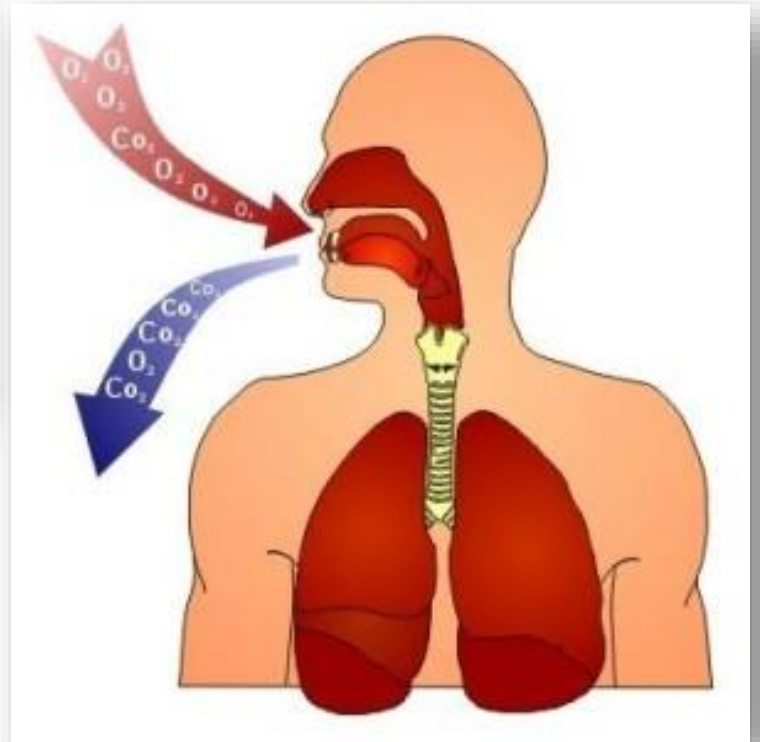
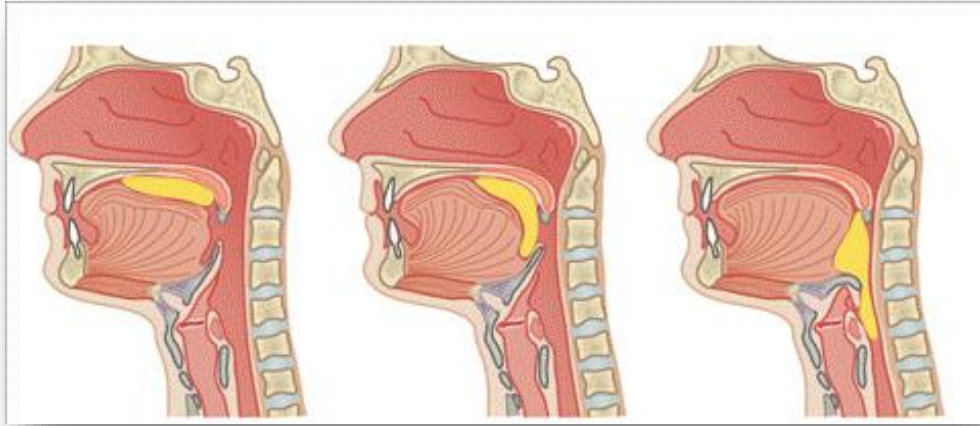





RESPIRARE

MASTICARE

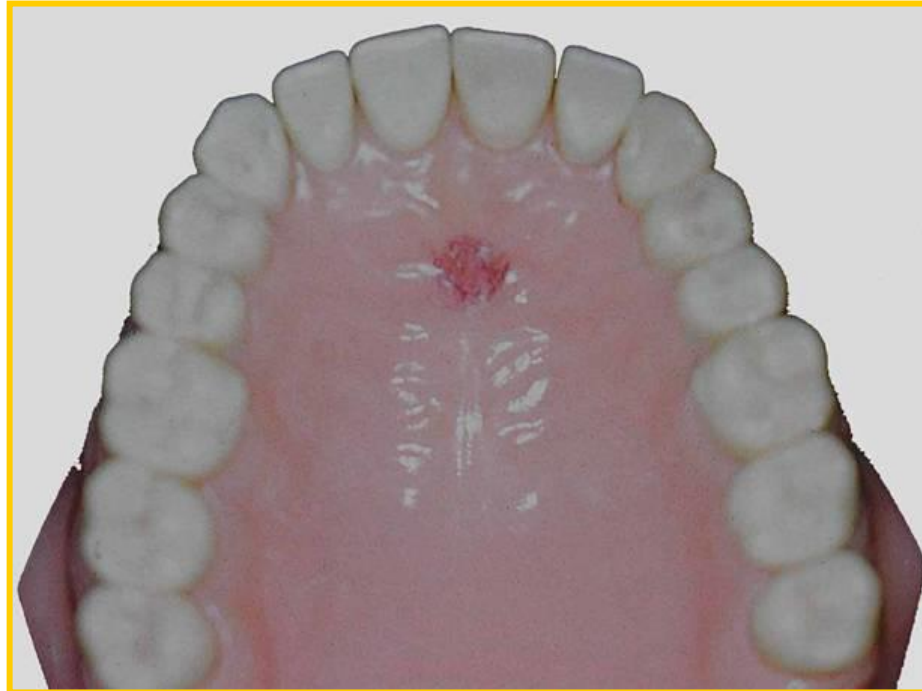DEGLUTIRE



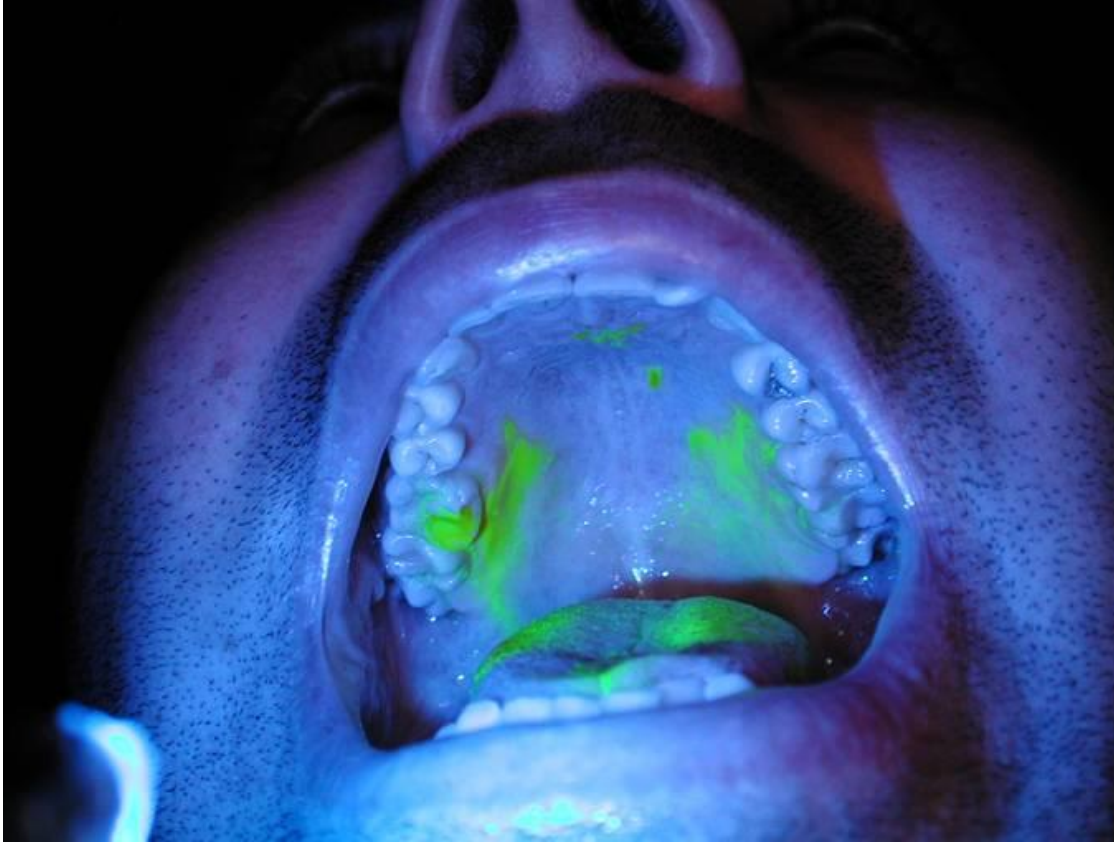# Airway and TMJ

Dental  Art 3D

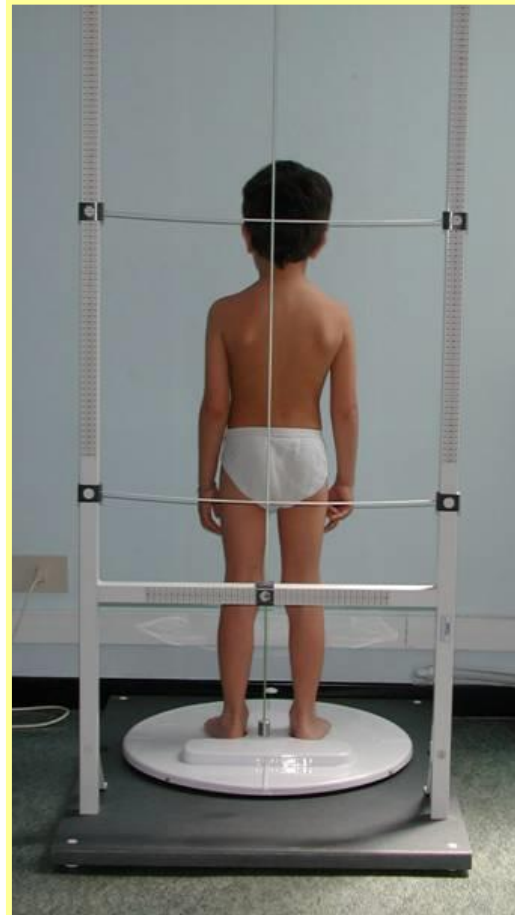The Full Version Is Available On: [tmd3d.com](http://tmd3d.com)



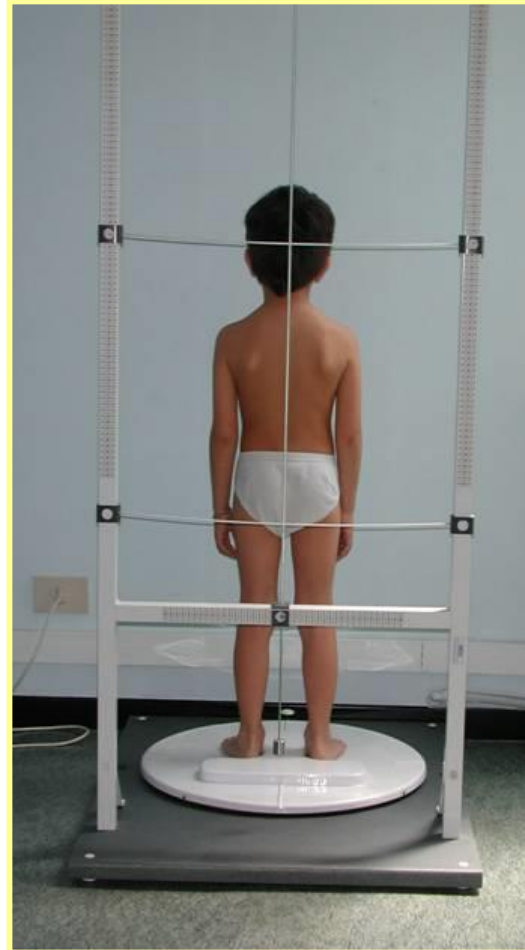**Spot linguale**




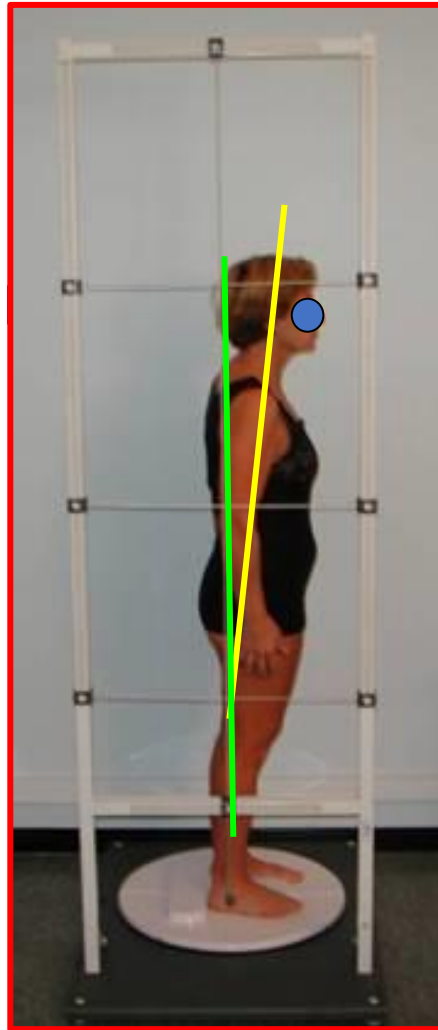
# Posizione normale

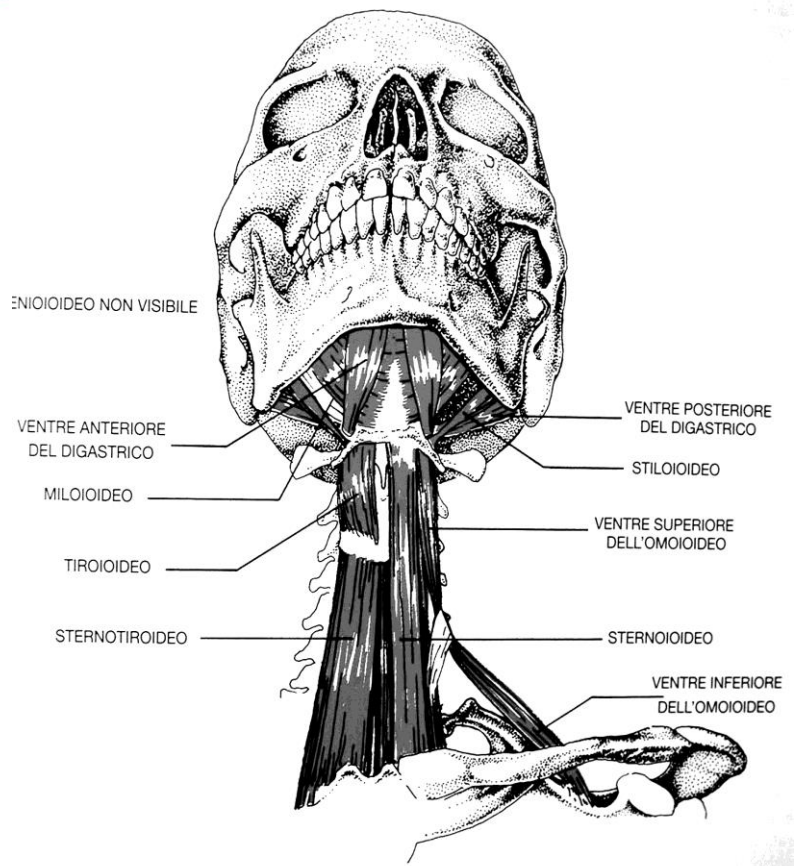


# Lingua allo spot

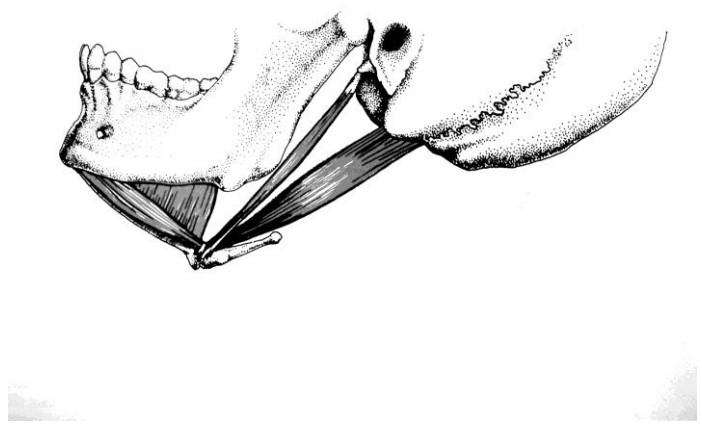


**Cambiamenti co  
lingua  
in posizione  
corretta**





**SOTTOIOIDEI**



**SOPRAIOIDEI**

## INSERZIONI PRESENTI SULL'OSSO IOIDE

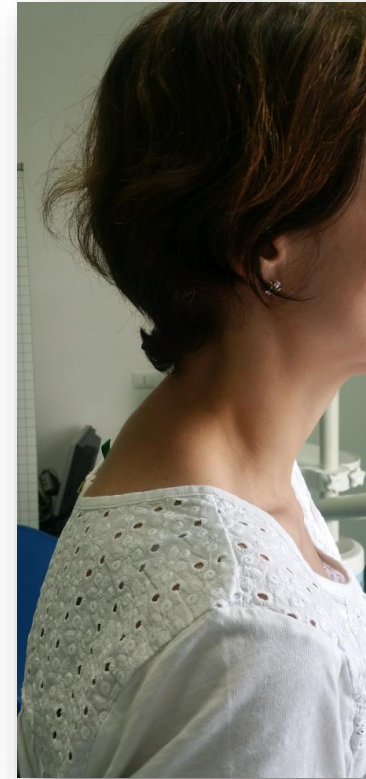
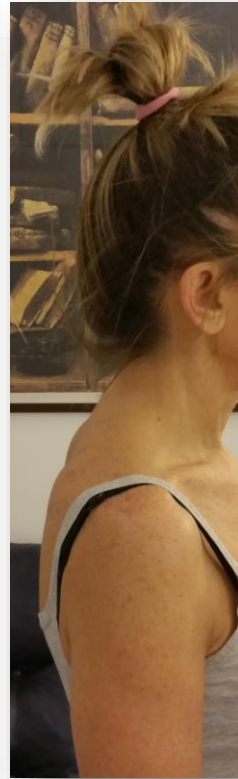### • MUSCOLI

- IOGLOSSO
- GENIOGLOSSO
- GENIOIOIDEO
- OMOIOIDEO
- MILOIOIDEO
- STERNOIOIDEO
- TIROIOIDEO
- DIGASTRICO
- CONDROGLOSSO
- COSTRITTORE MEDIO DEL FARINGE
  - (talora elevatore della tiroide)
  - (talora sternotiroideo)

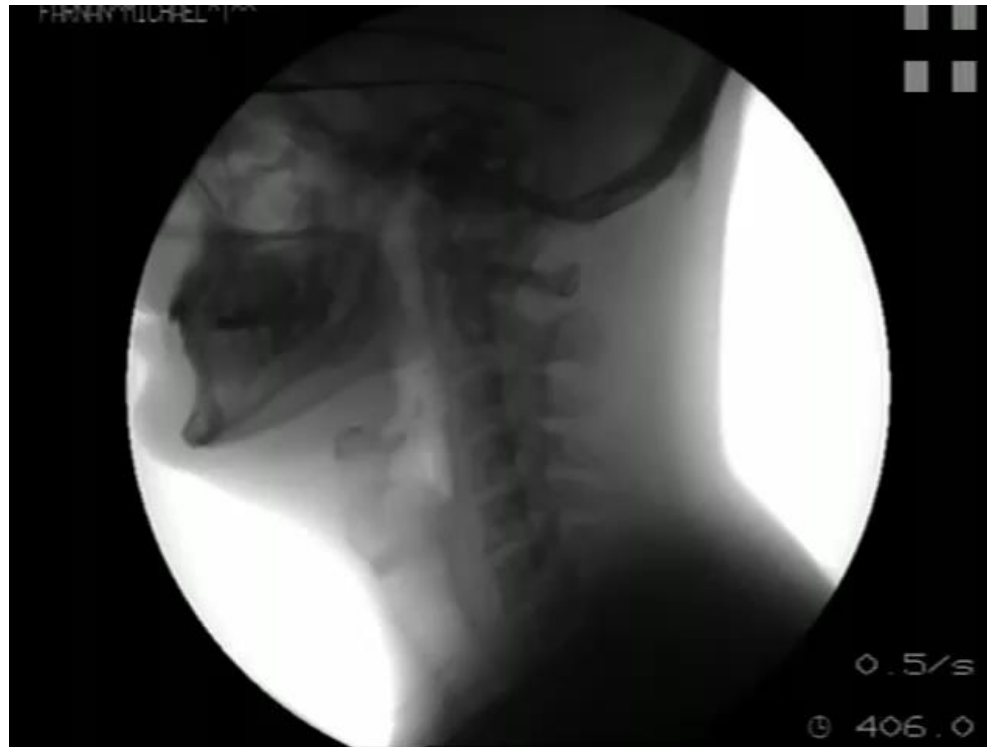### • LEGAMENTI

- IO-EPIGLOTTICO
- TIROIDEO LATERALE
- STILOIOIDEO
- STILOIOIDEO

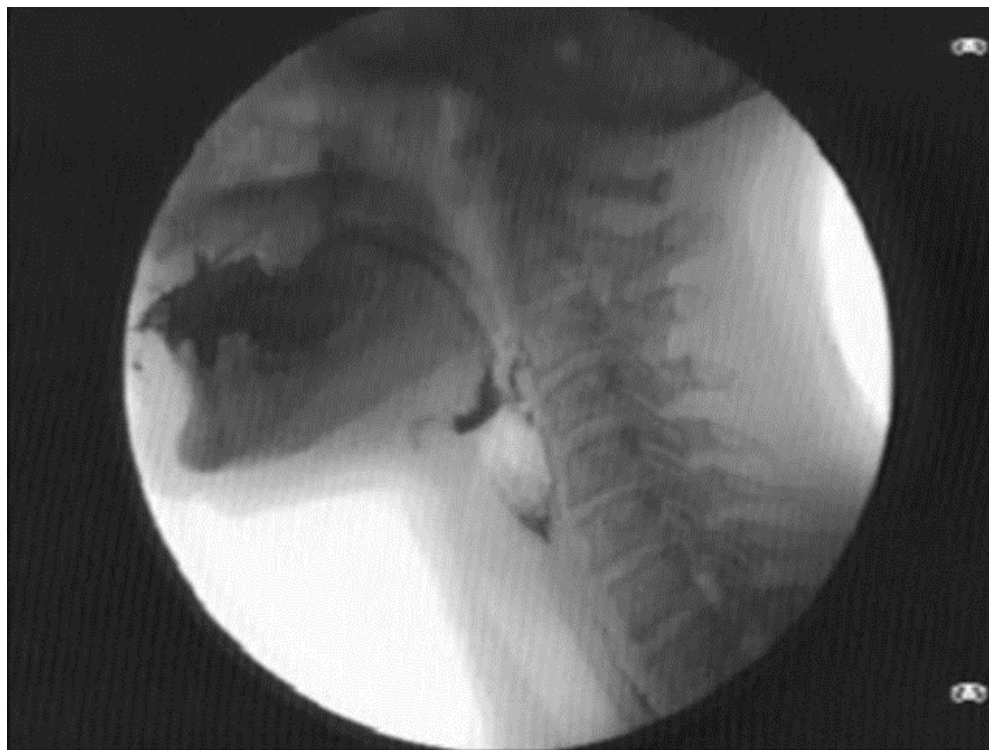# Postura da deglutizione scorretta

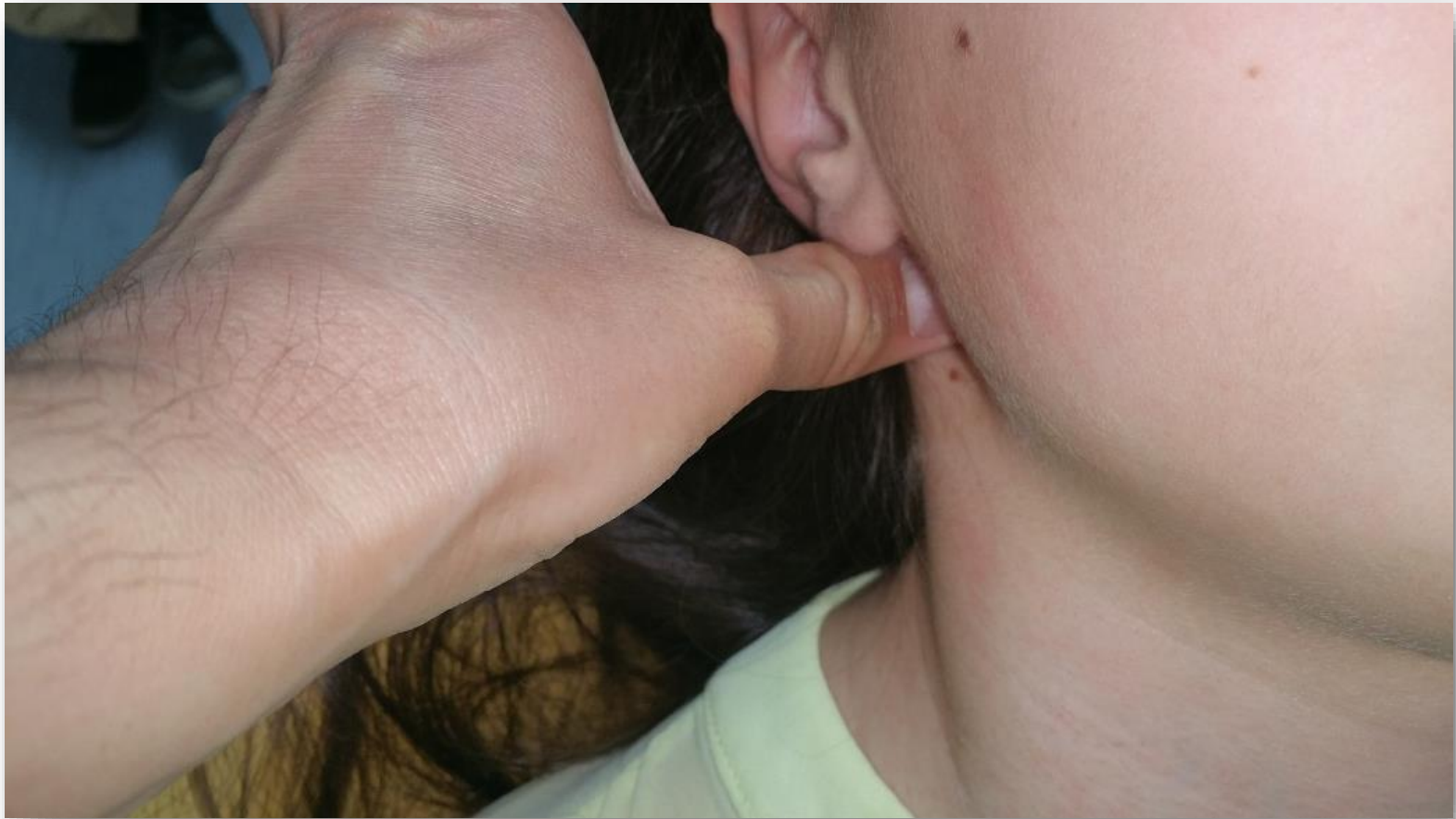

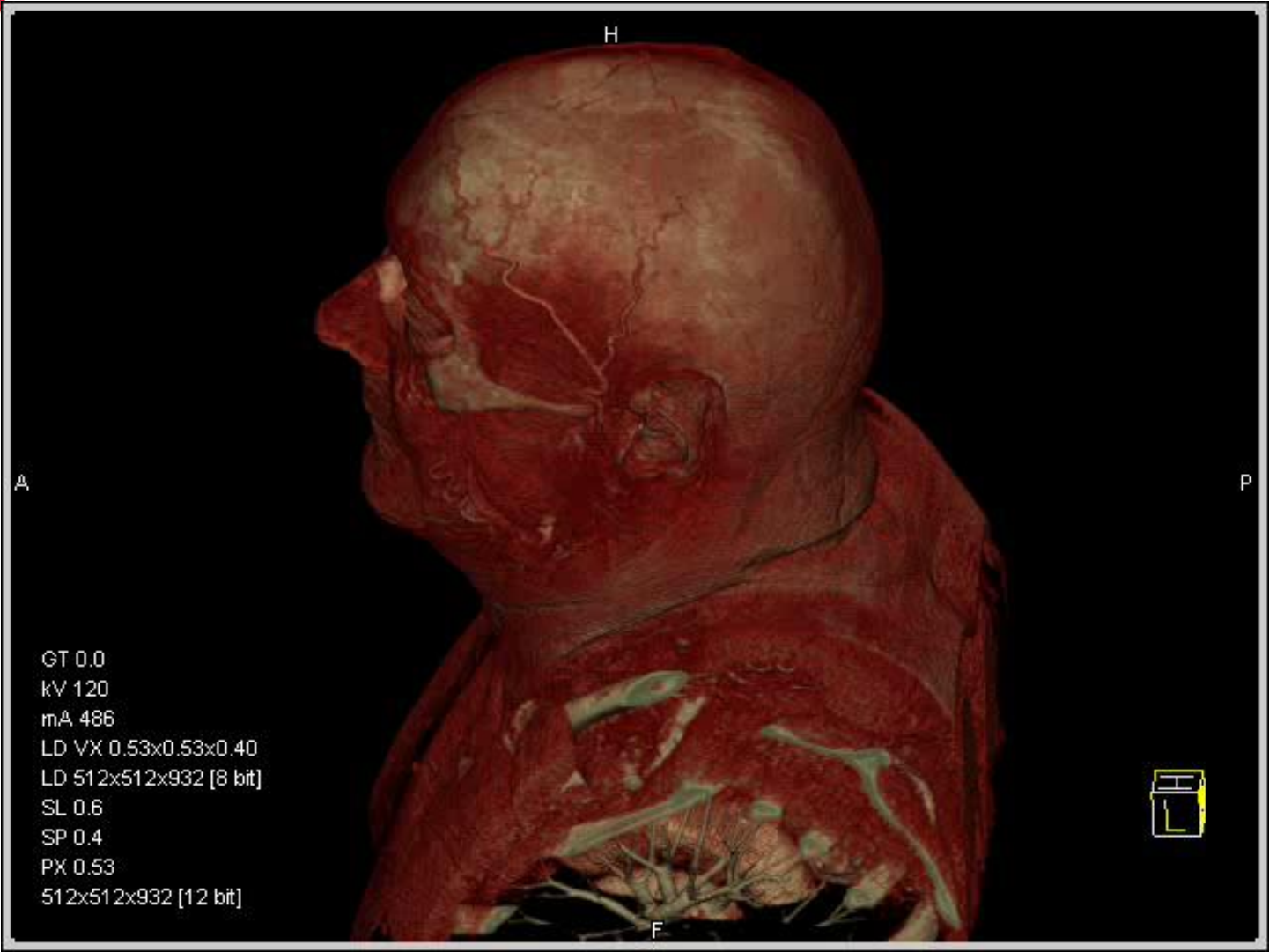# Deglutizione corretta

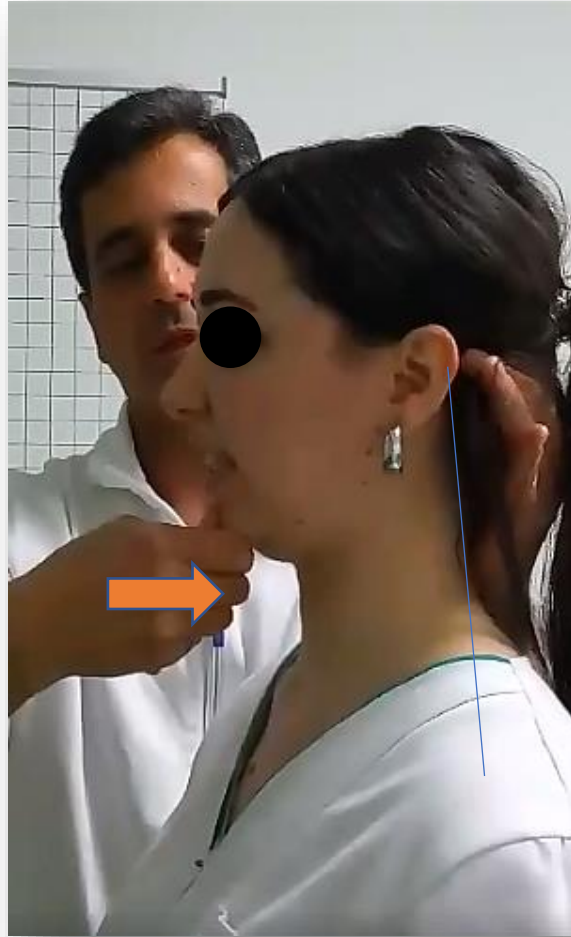
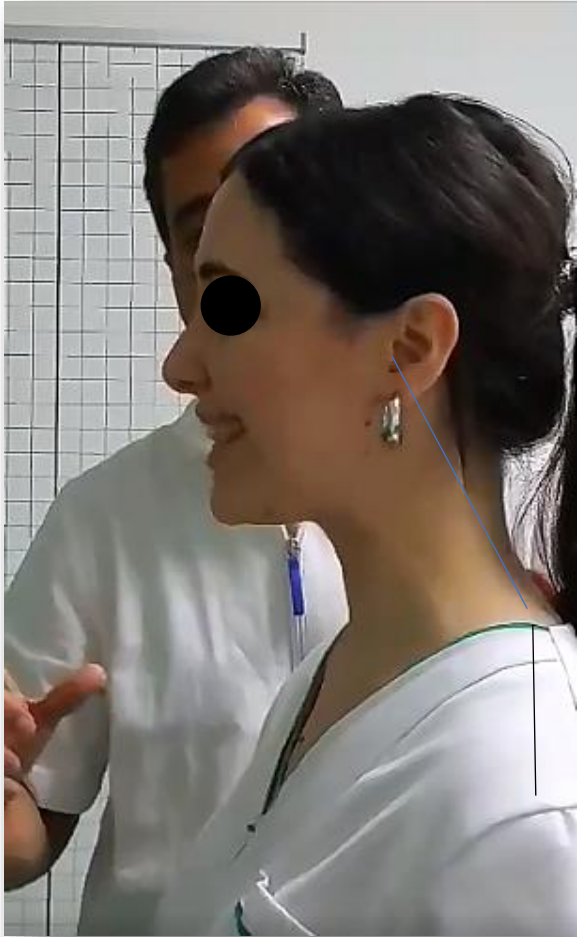
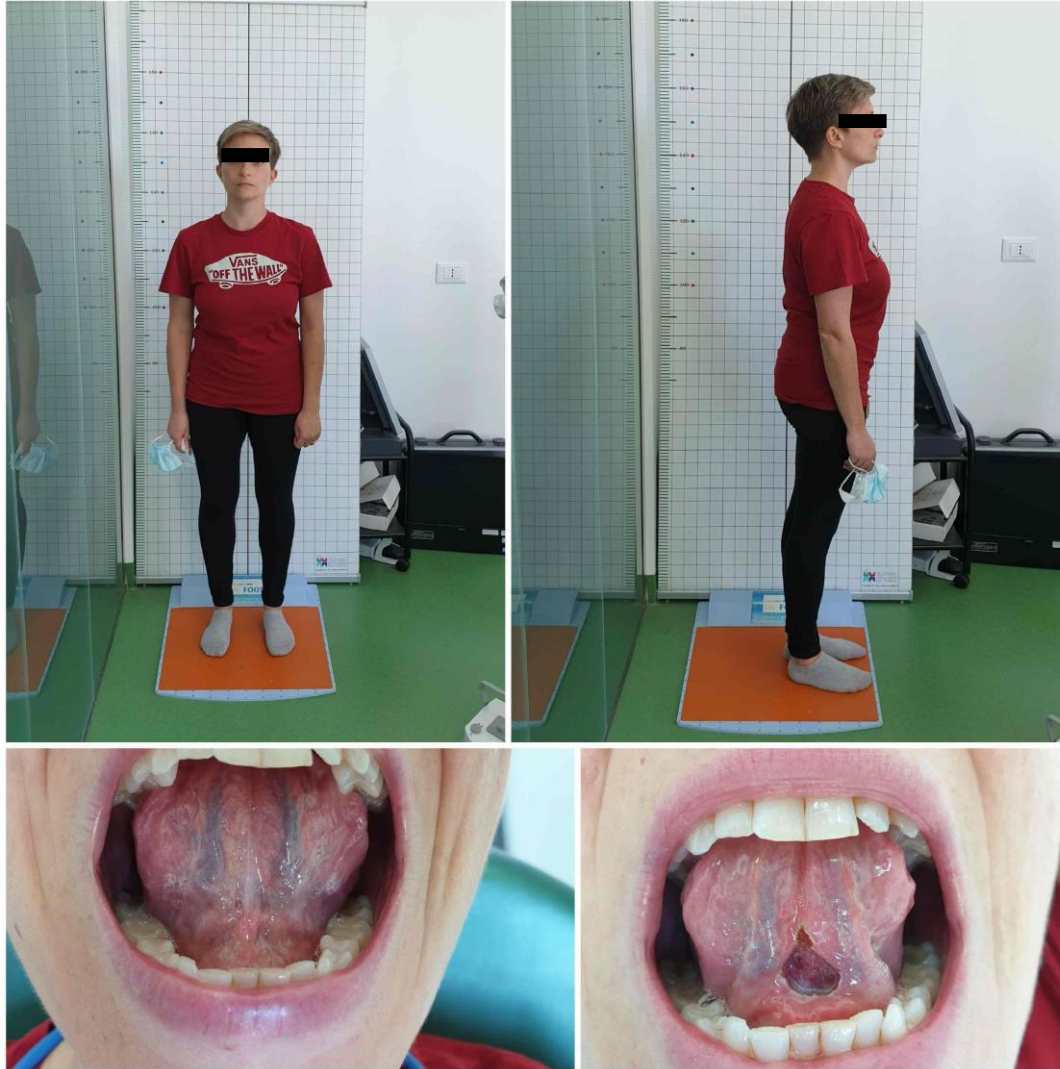# Deglutizione Scorretta

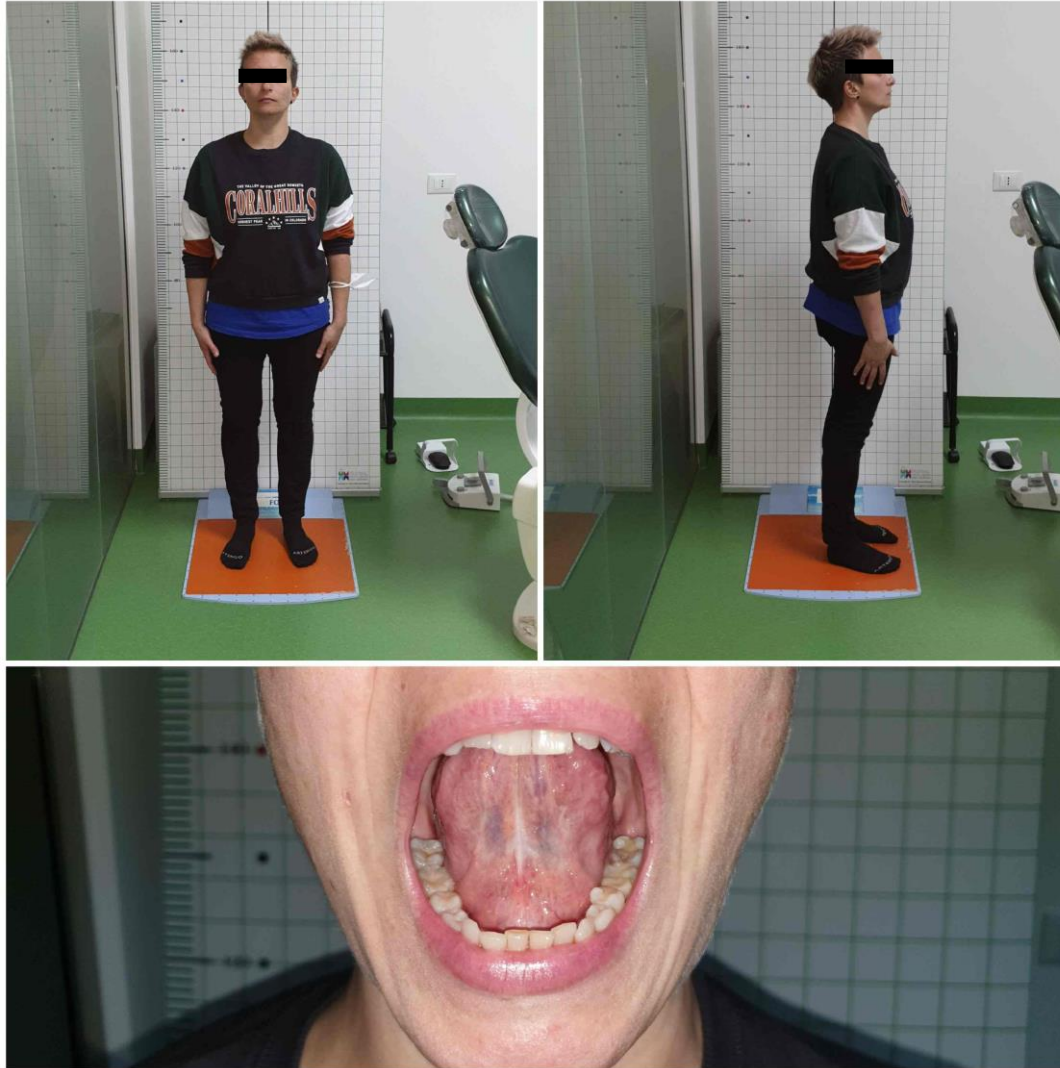






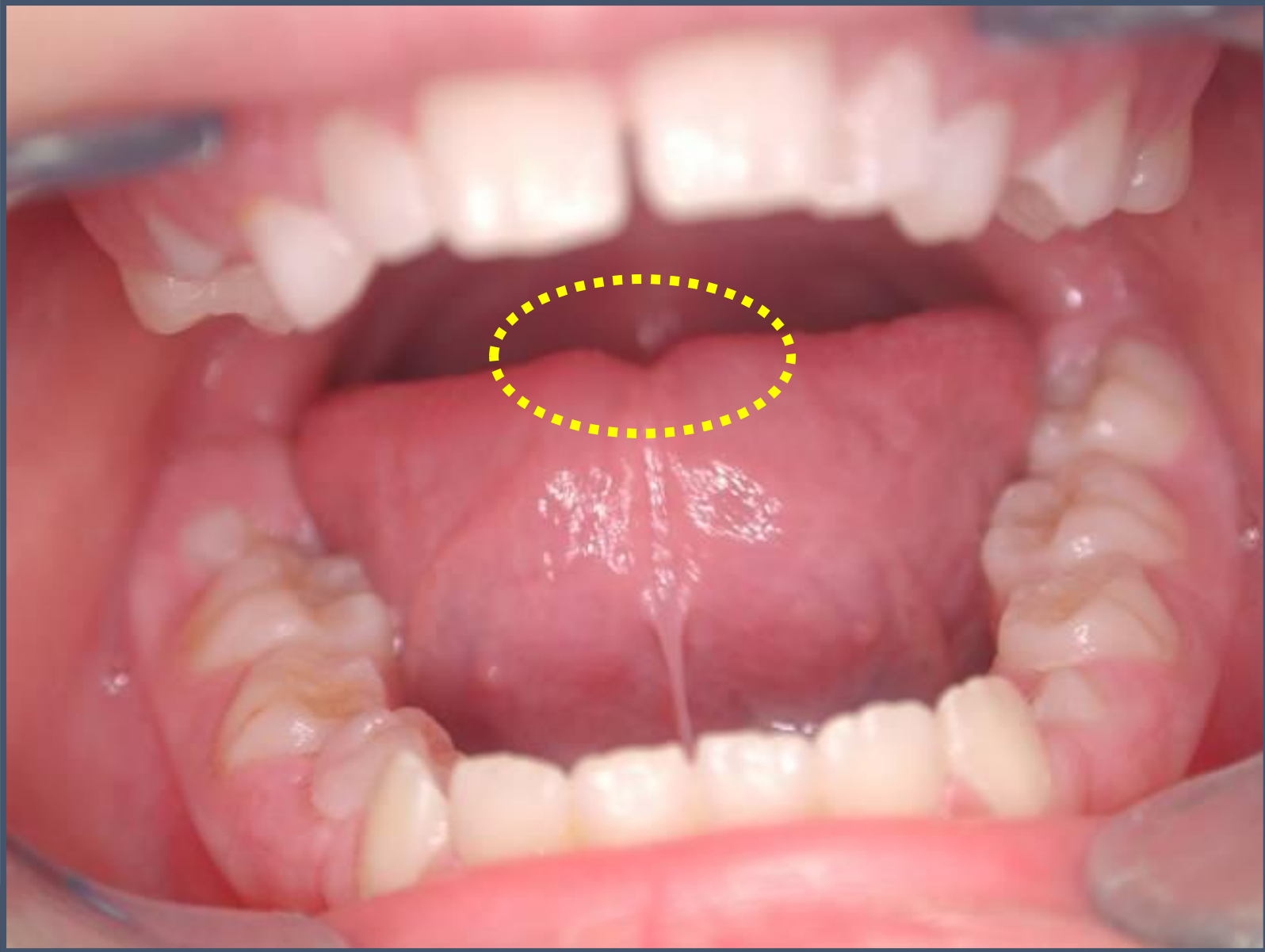


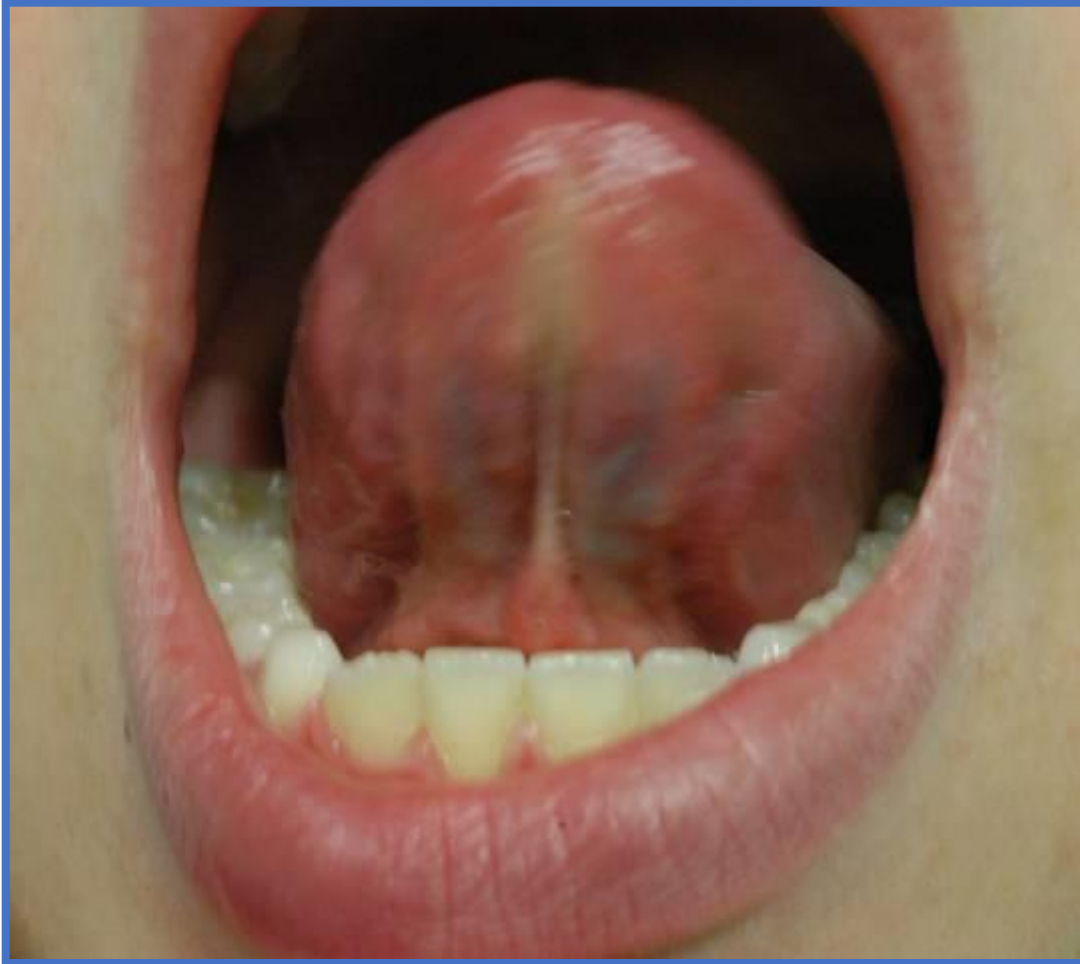


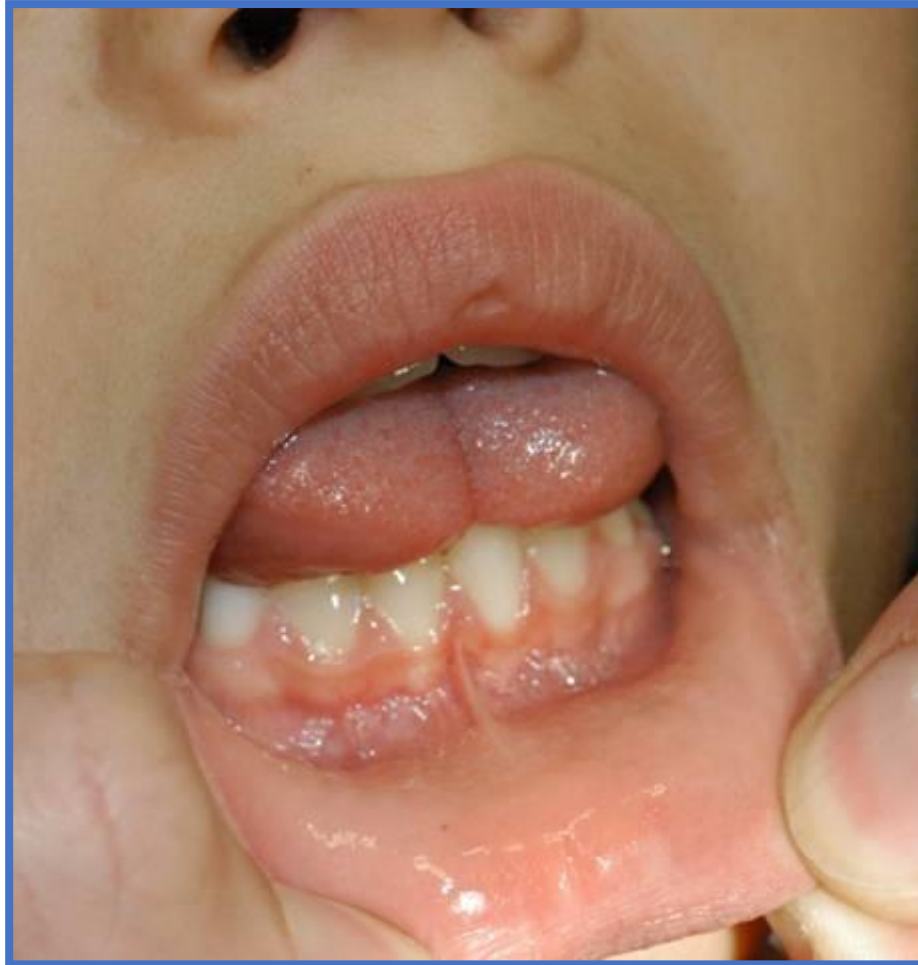


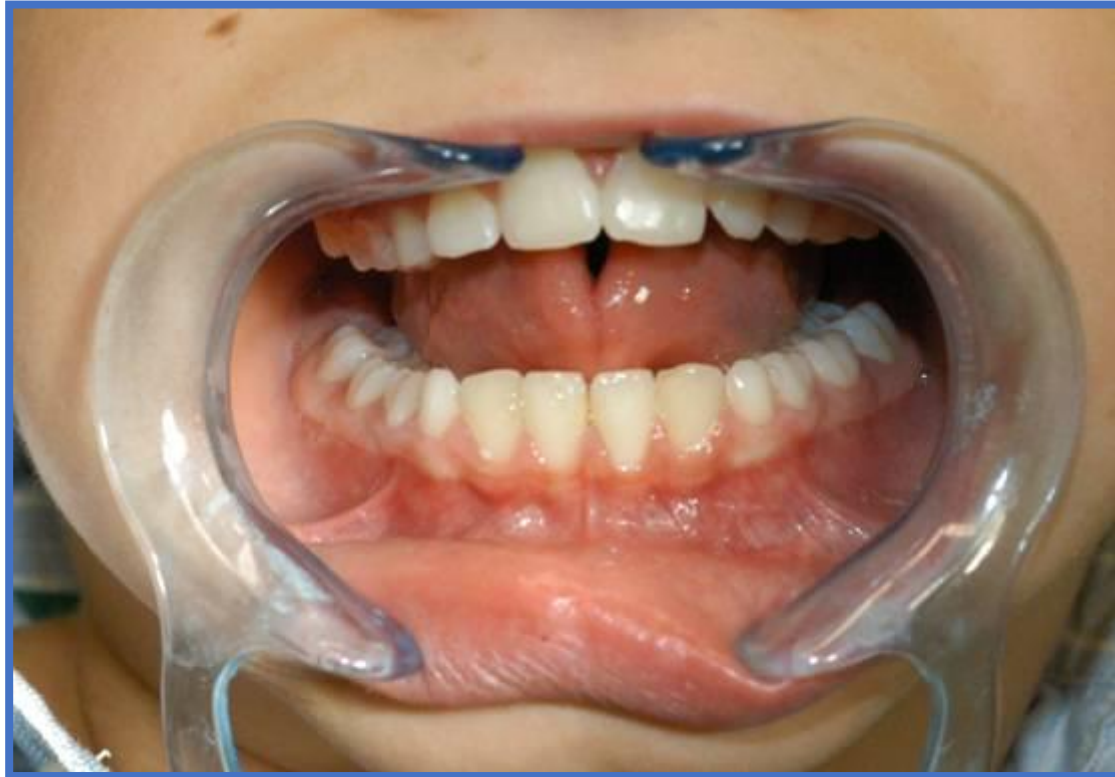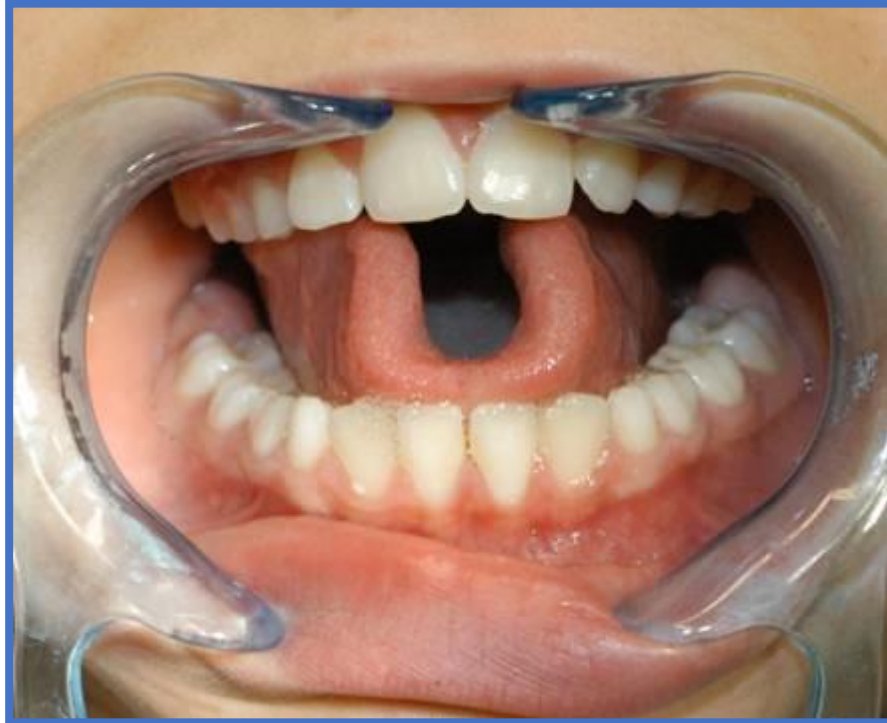# Frenulo linguale corto

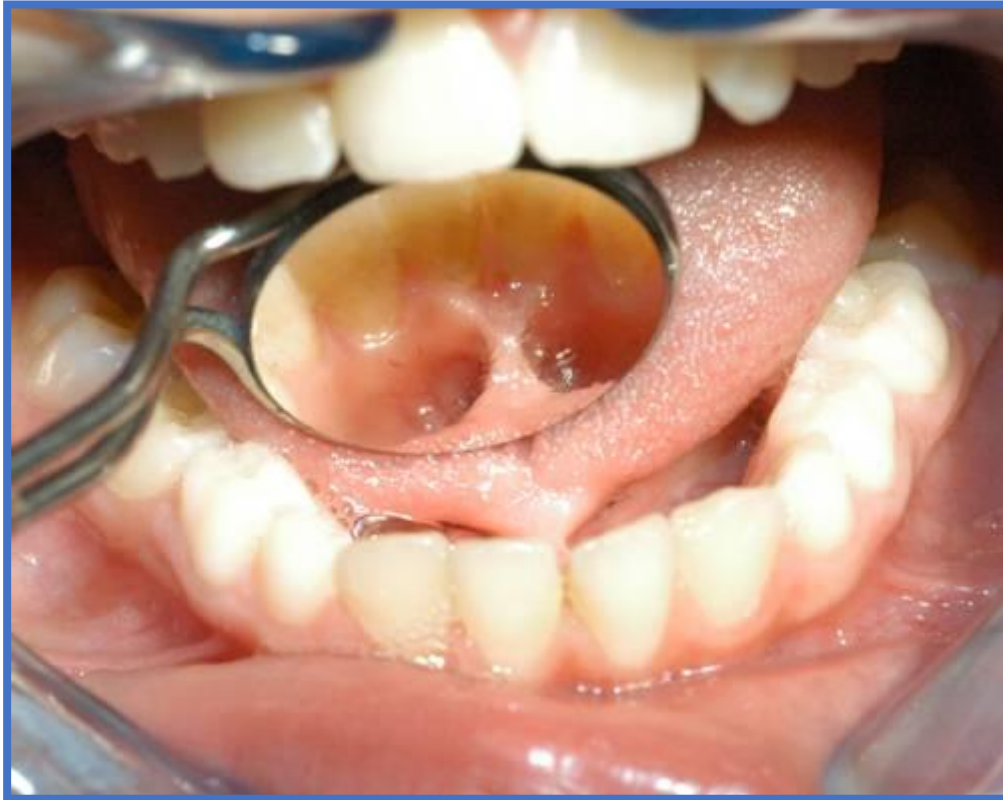

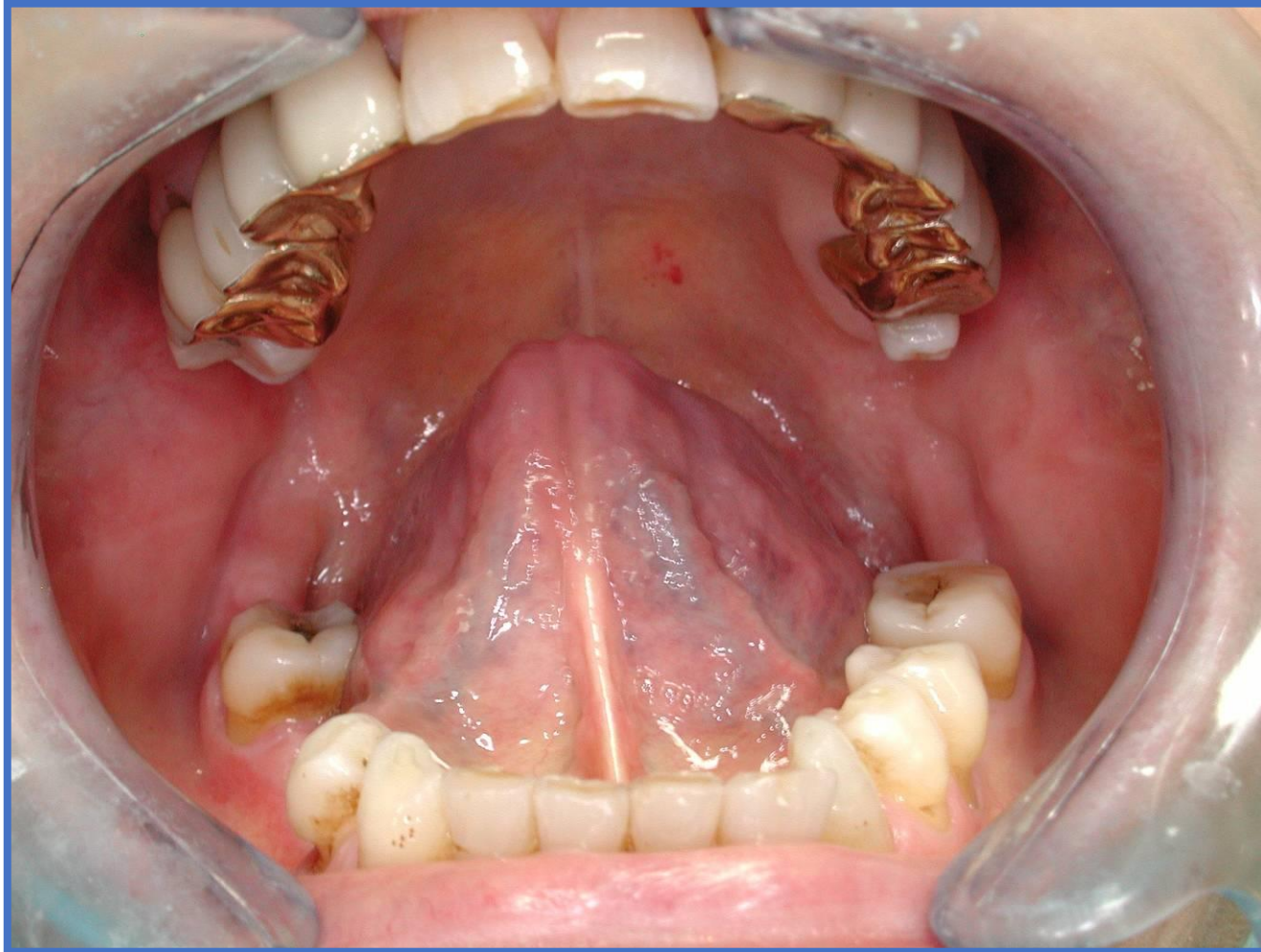



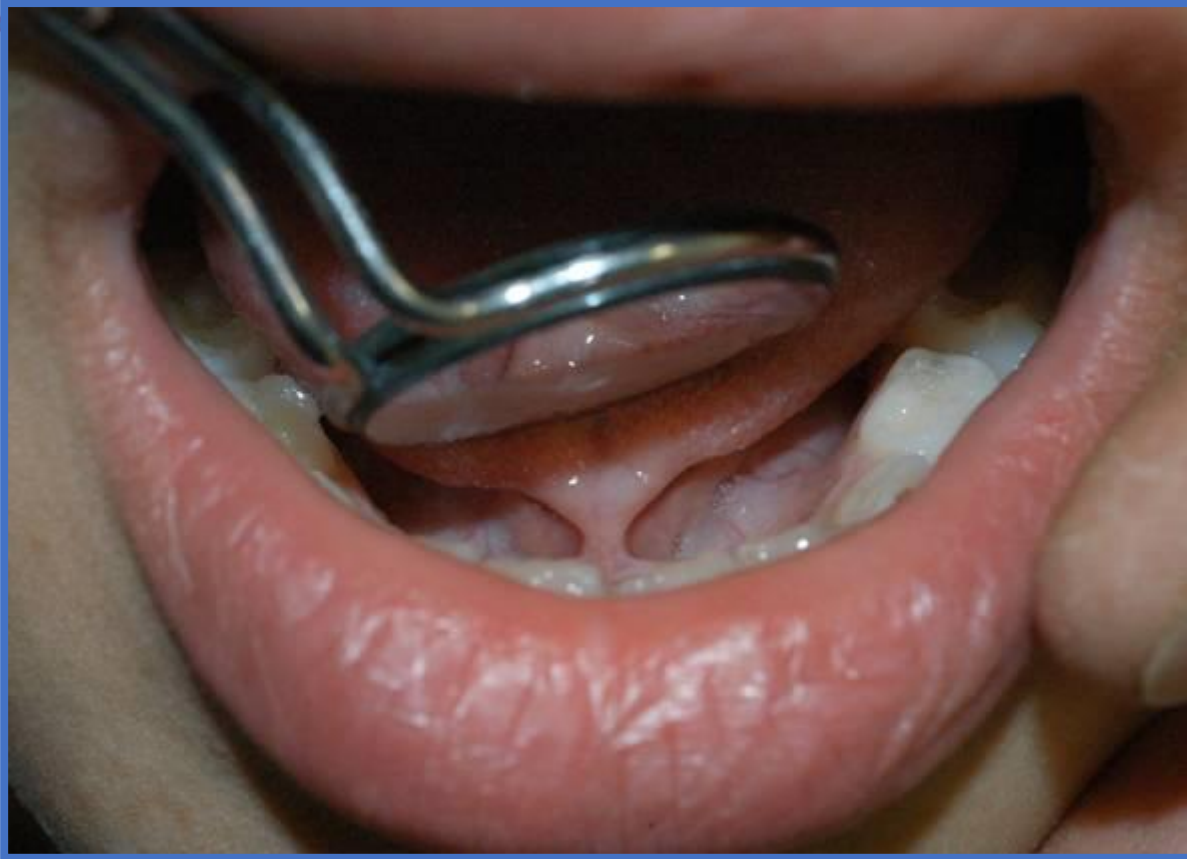




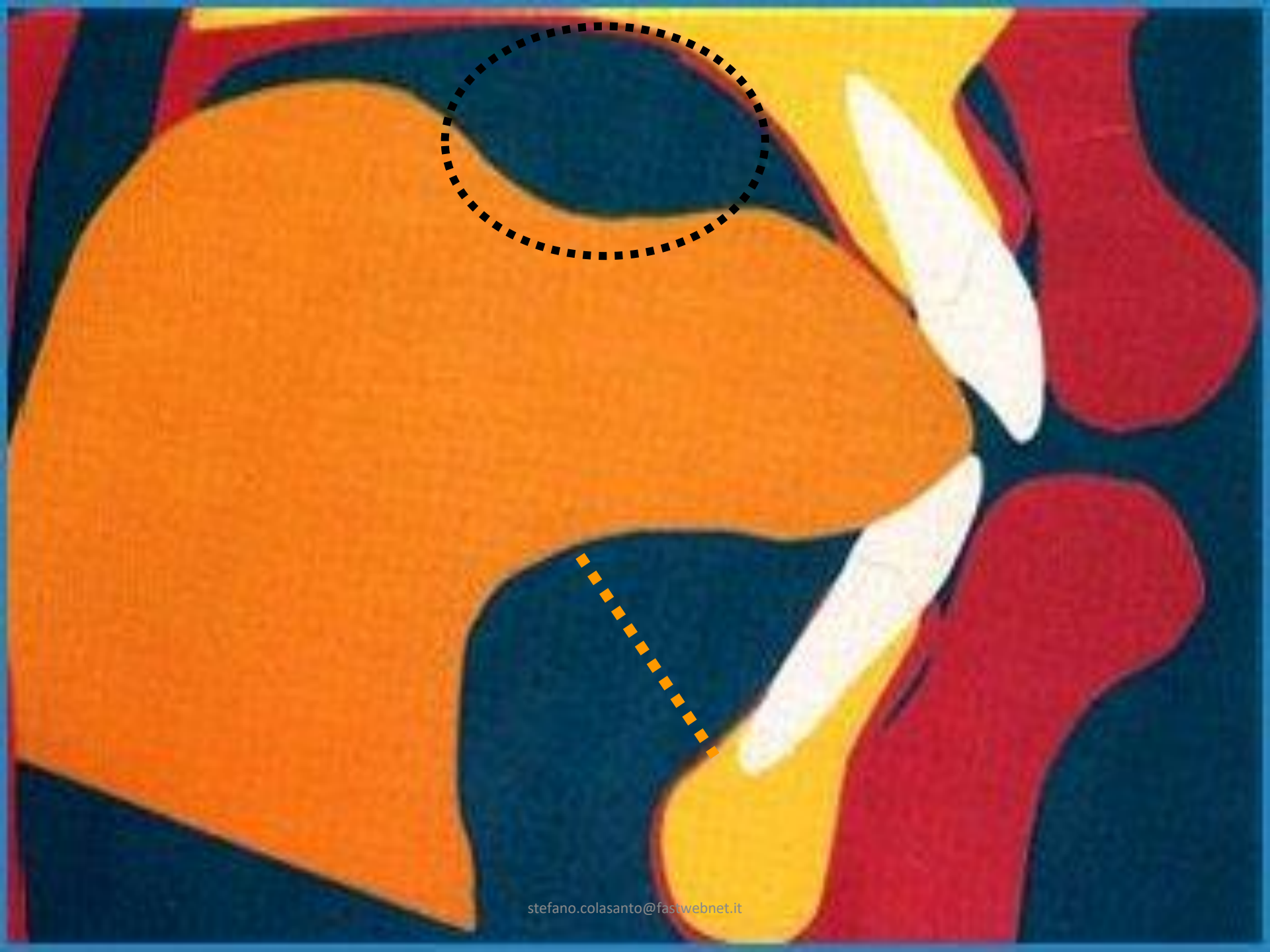


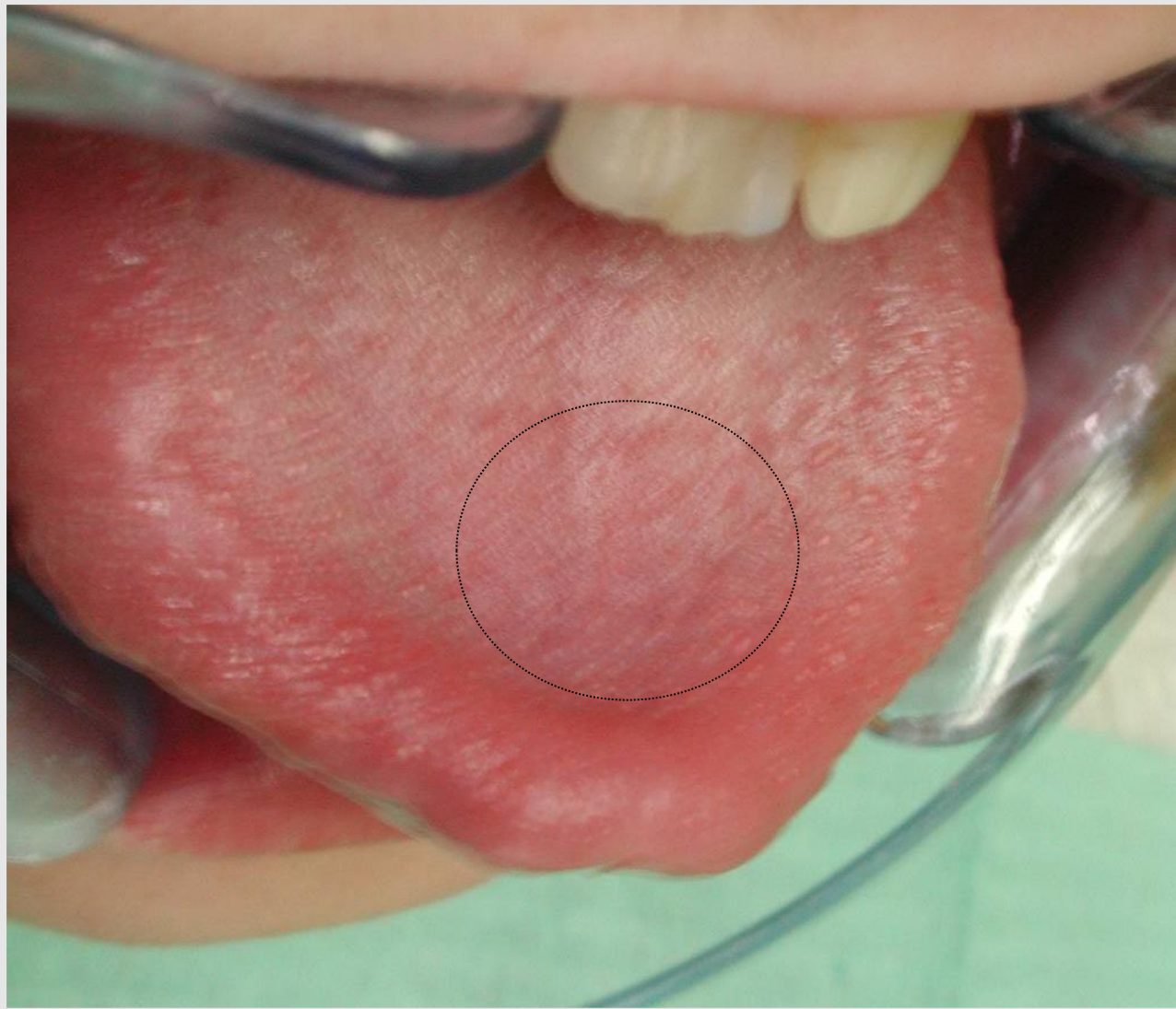


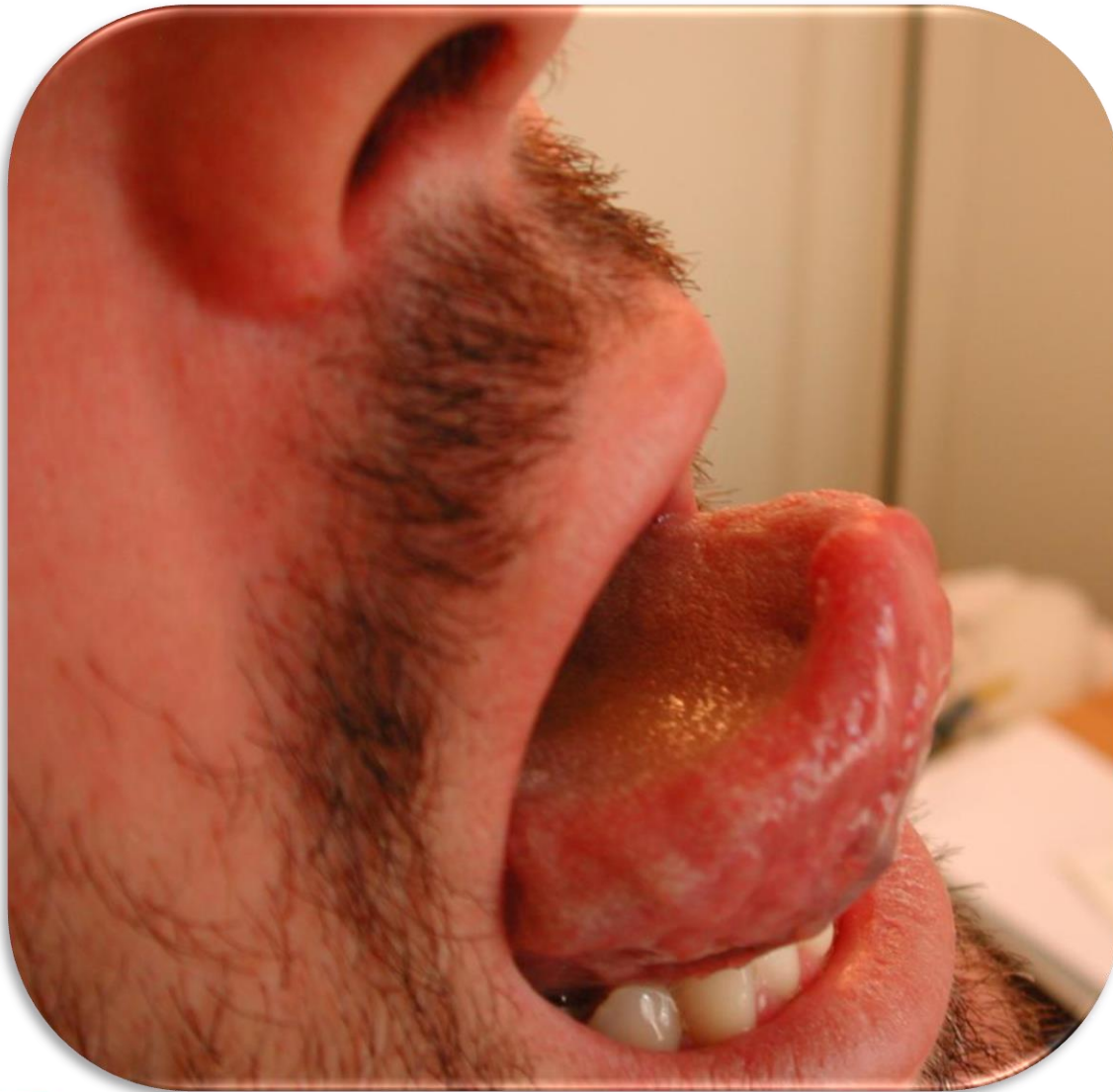


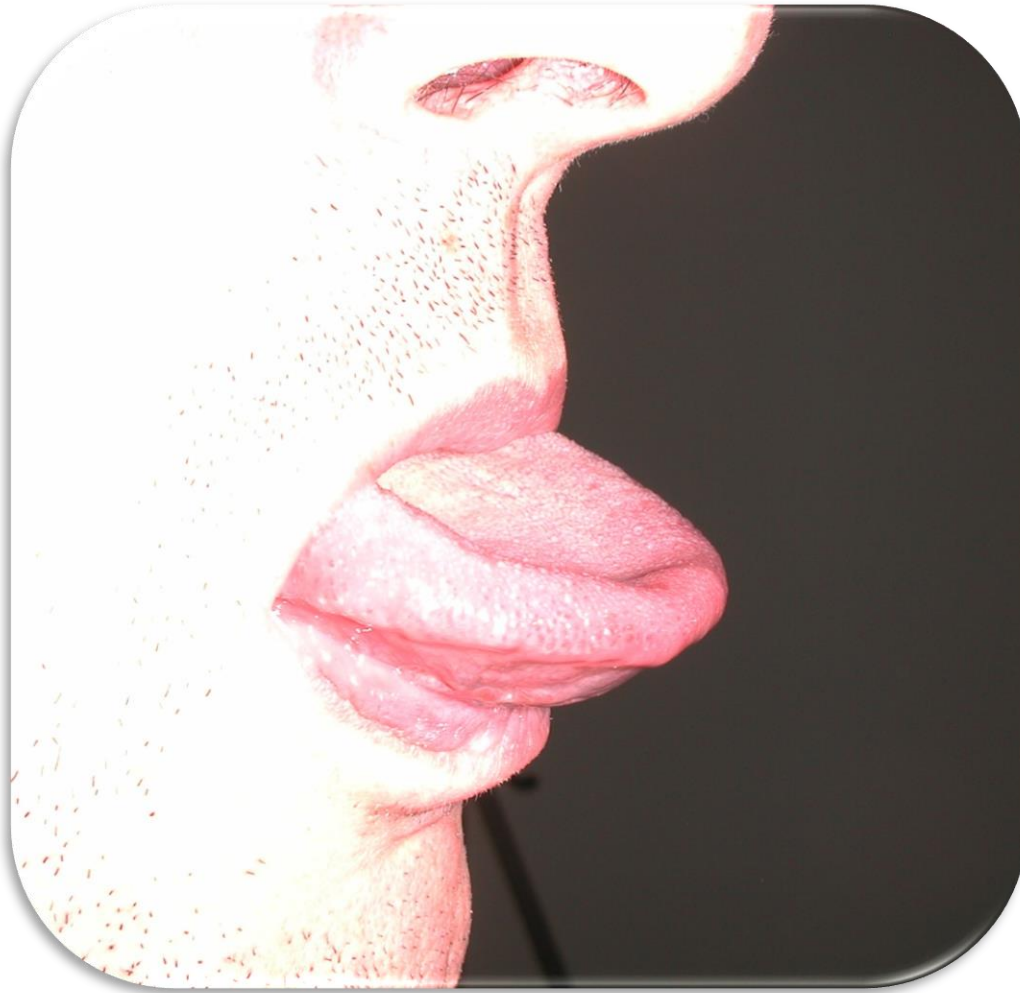**Attenzione anche alla forma  
della lingua!**

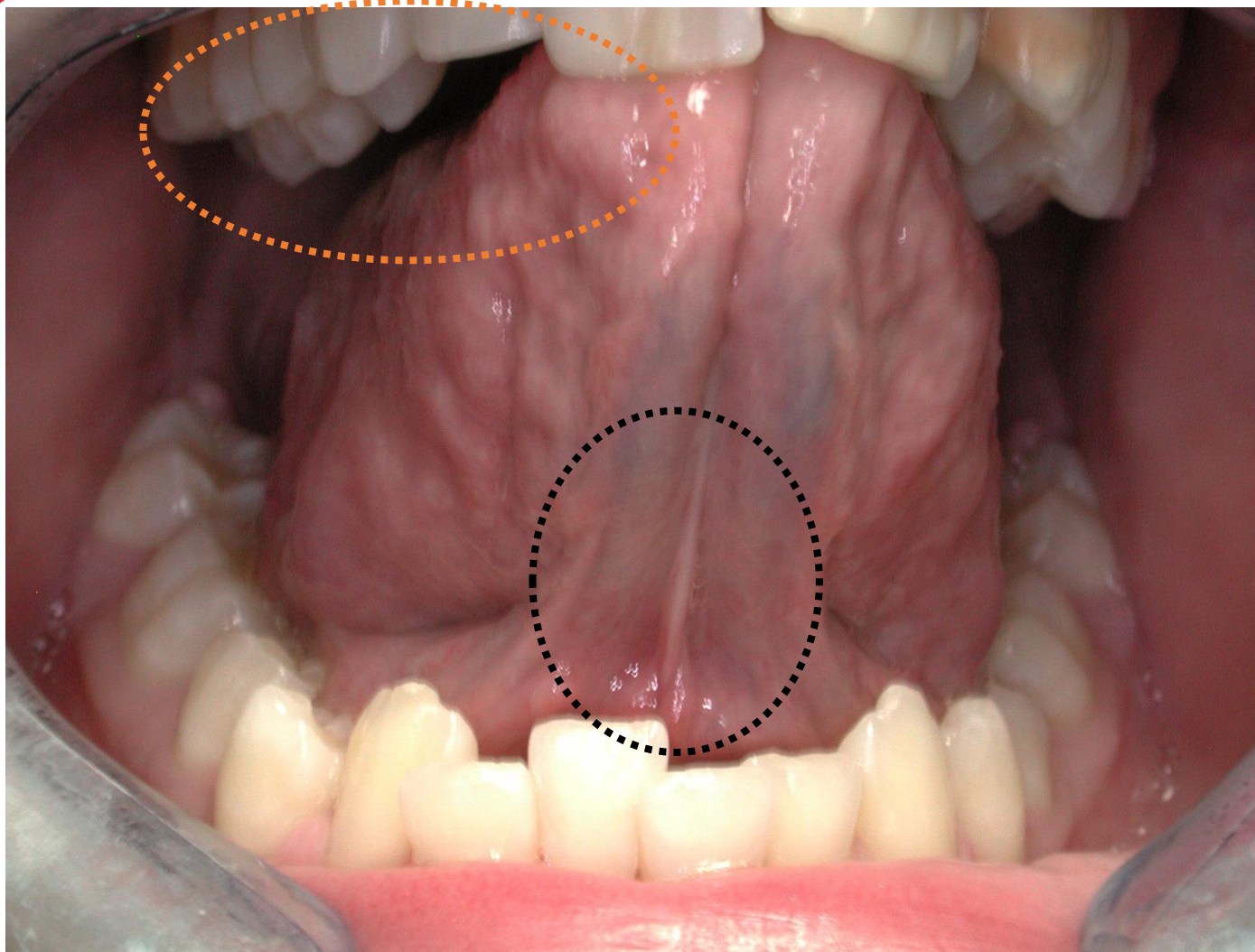




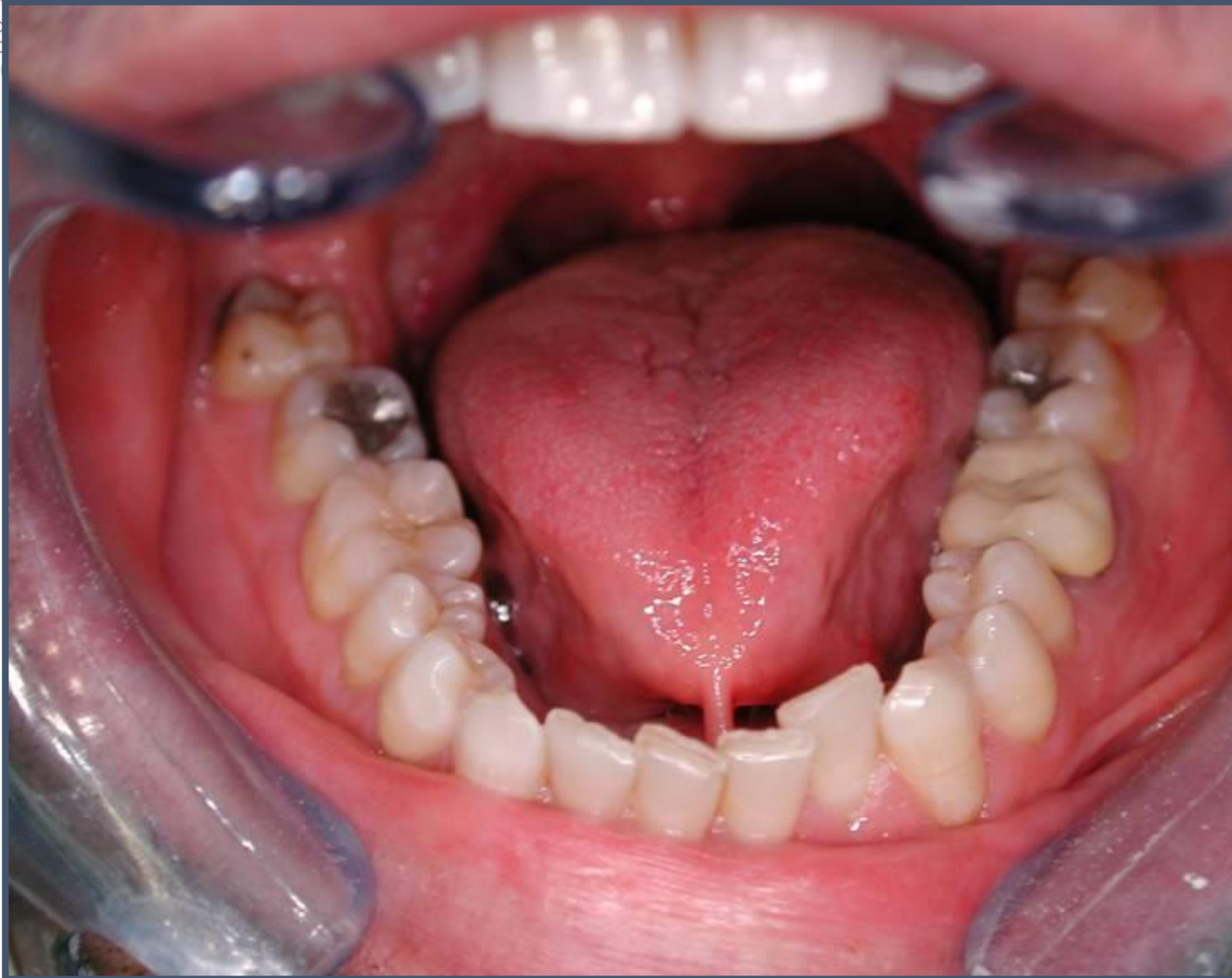


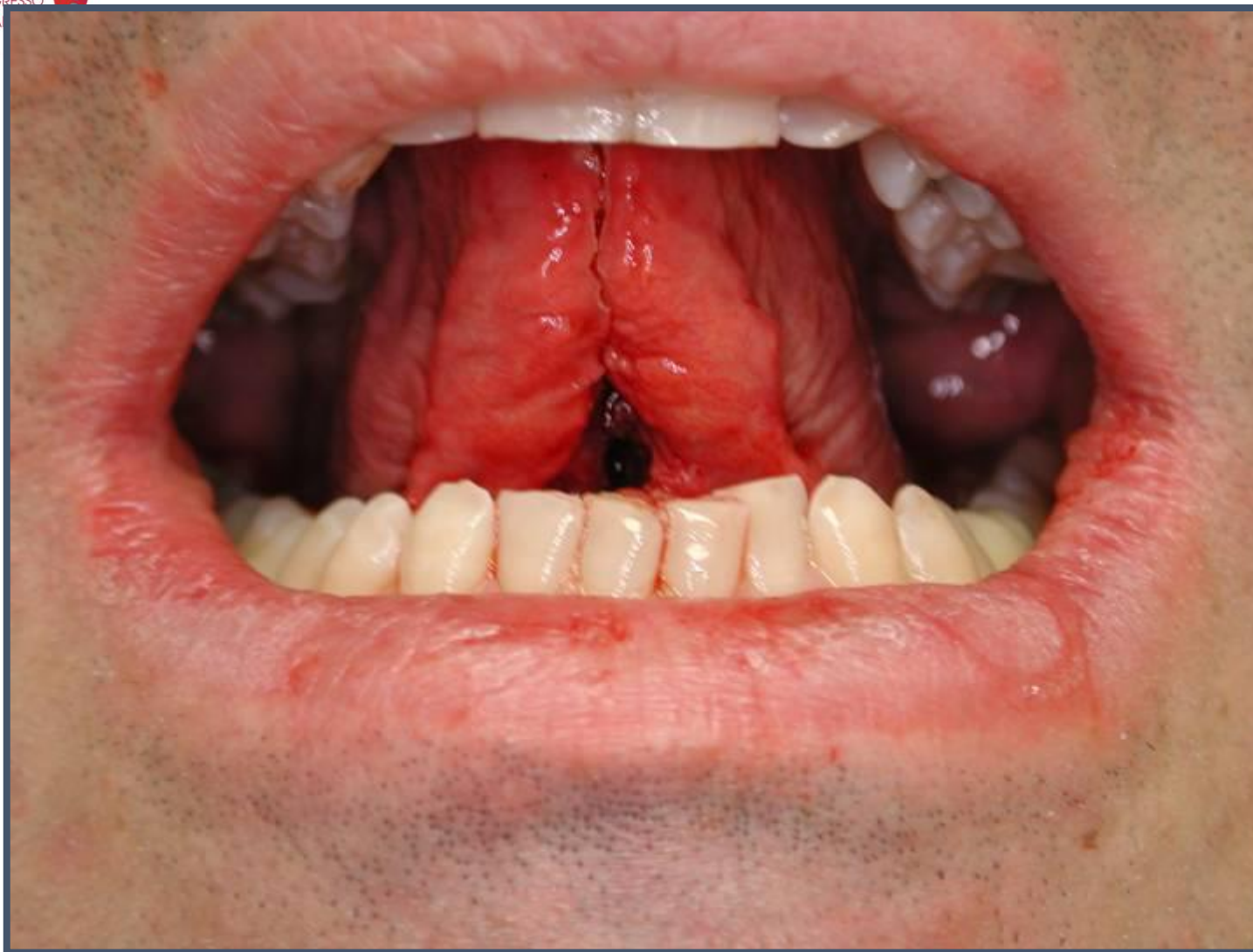


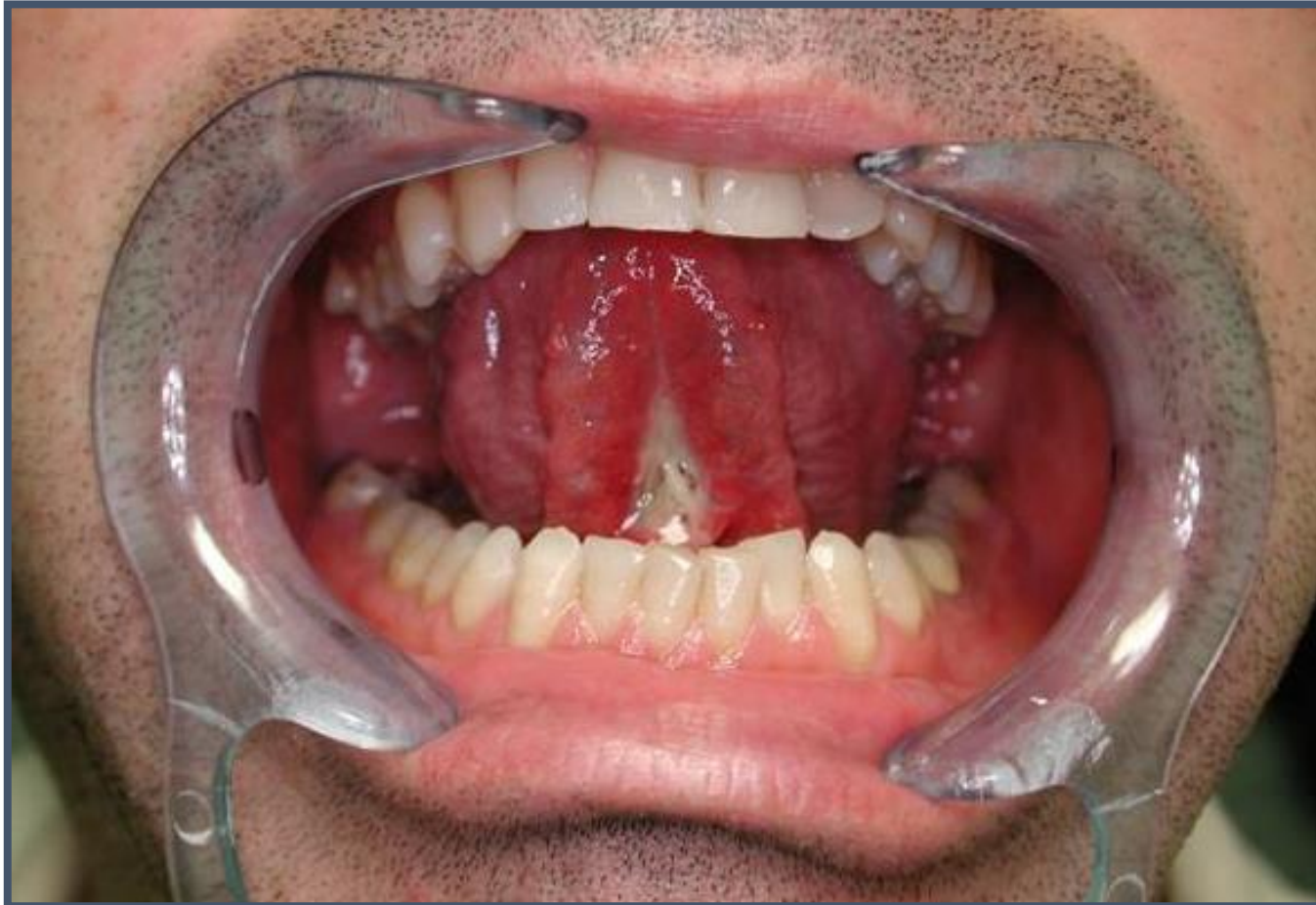

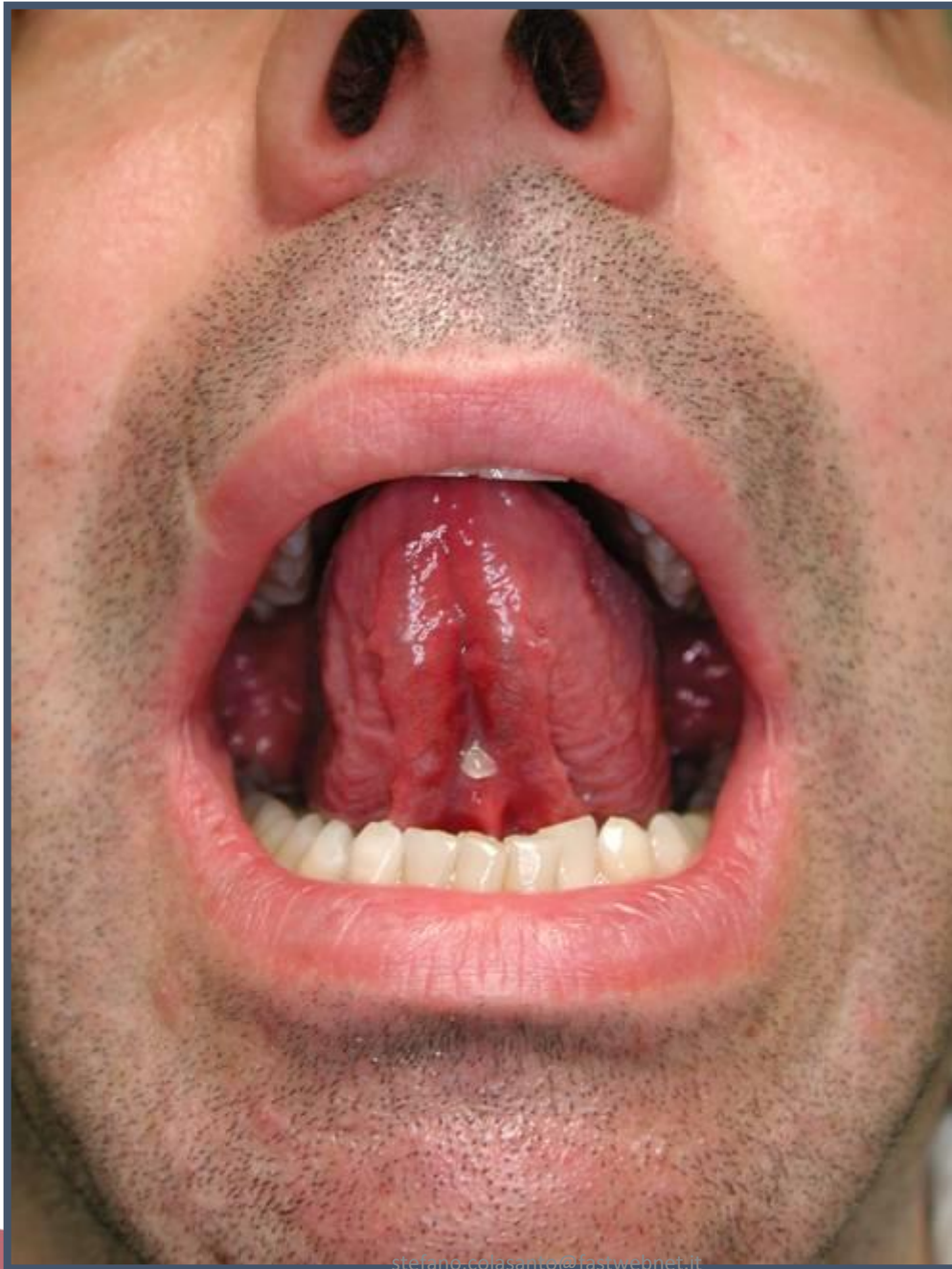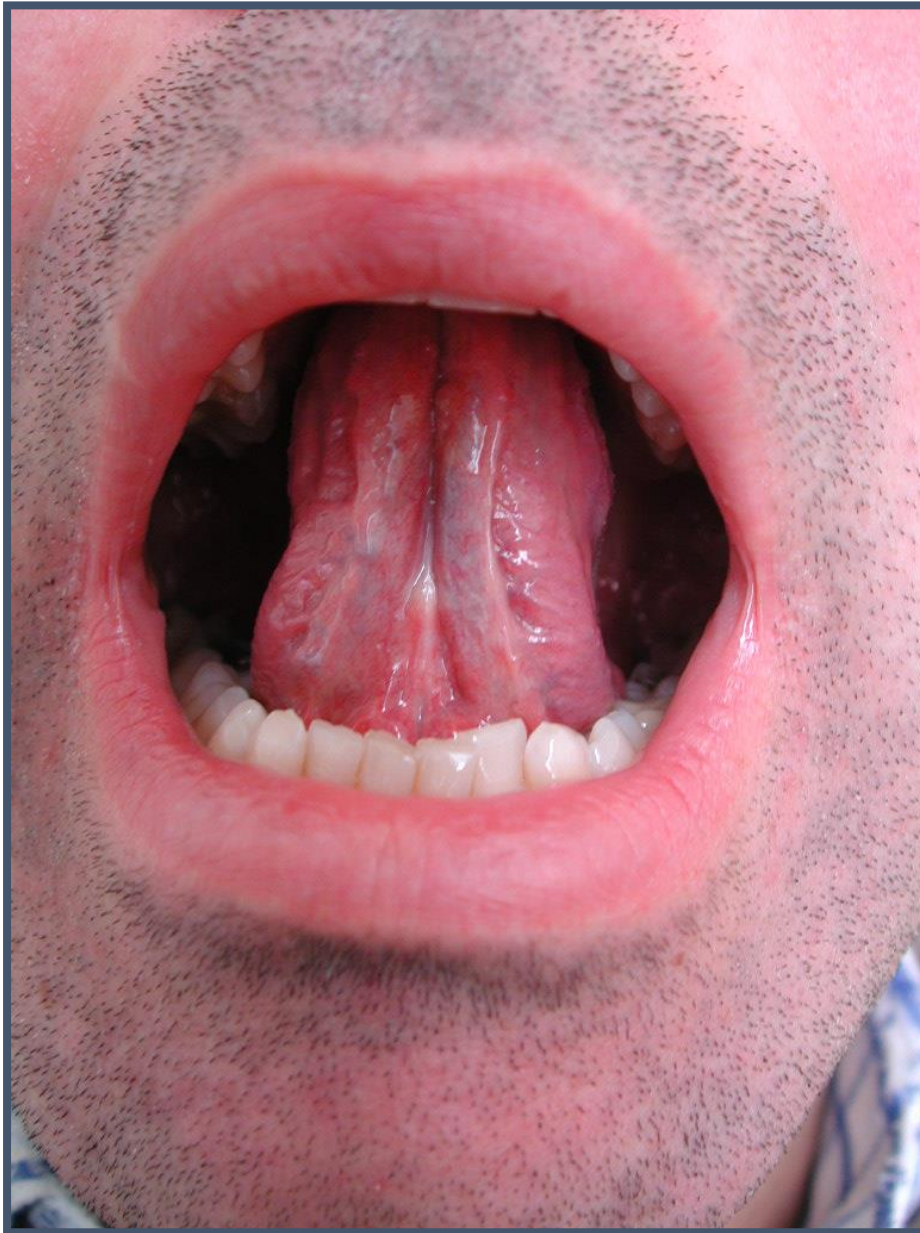**La soluzione è chirurgia + TMF**













**30 ANNI DI OSTEOPATIA IN ITALIA**  
SVILUPPO, RICERCA E IDENTITÀ  
24 - 25 - 26 GIUGNO 2022

**Grazie per l'attenzione**